GHADIALI

GHADIALI
General Surgery

PRESENTS

Dr. Mufa T. Ghadiali is skilled in all aspects of General Surgery.
His General Surgery Services include:

- General Surgery
- Advanced Laparoscopic Surgery
- Surgical Oncology
- Gastrointestinal Surgery
- Hernia Surgery
- Endoscopy

Hydrocephalus

Multimedia Health Education

Disclaimer

This movie is an educational resource only and should not be used to manage your health. All decisions about the management of hydrocephalus must be made in conjunction with your Physician or a licensed healthcare provider.

Mufa T. Ghadiali, M.D., F.A.C.S

Diplomate of American Board of Surgery

6405 North Federal Hwy., Suite 402
Fort Lauderdale, FL 33308

Tel.: 954-771-8888
Fax: 954- 491-9485

www.ghadialisurgery.com

MULTIMEDIA HEALTH EDUCATION MANUAL

TABLE OF CONTENTS

SECTION	CONTENT
1 . Normal Brain Anatomy	
a.	Introduction
b.	Normal Brain Anatomy
2 . Overview of Hydrocephalus	
a.	What Hydrocephalus?
B.	Types of Hydrocephalus?
c.	Symptoms
d.	Causes
3 . Treatment Options	
a.	Diagnosis
b.	Treatment Overview
c.	Surgical Treatment
d.	Post Operative Guidelines
e.	Risks and Complications

INTRODUCTION

Hydrocephalus is a condition in which the primary characteristic is excessive accumulation of fluid in the brain. Although hydrocephalus was once known as "water on the brain," the "water" is actually cerebrospinal fluid (CSF) — a clear fluid that surrounds the brain and spinal cord. The excessive accumulation of CSF results in an abnormal widening of spaces in the brain called ventricles. This widening creates potentially harmful pressure on the tissues of the brain.

In order to learn more about Hydrocephalus, it helps to understand the normal anatomy of the brain.

GHADIALI

Normal Brain Anatomy

The brain is the most complex part of the human body. This three-pound organ is the seat of intelligence, interpreter of the senses, initiator of body movement, and controller of behavior.

Lying in its bony shell and washed by protective fluid, the brain is the source of all the qualities that define our humanity.

(Refer fig.1)

(Fig.1)

Sections of the Brain

All the parts of the brain work together, but each part has its own special properties. The brain can be divided into three basic units: the forebrain, the midbrain, and the hindbrain.

Forebrain:

The forebrain is the largest and most highly developed part of the human brain. It consists primarily of the cerebrum and structures of the inner brain.

(Refer fig.2)

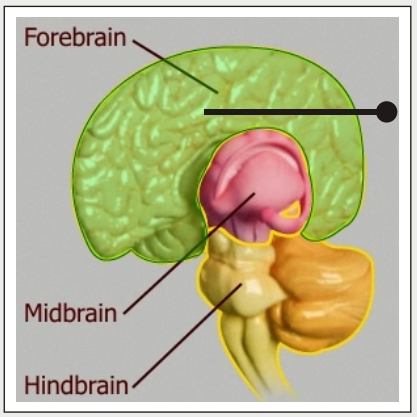

Forebrain

(Fig.2)

Midbrain:

The uppermost part of the brainstem is the midbrain, which controls some reflex actions and is part of the circuit involved in the control of eye movements and other voluntary movements.

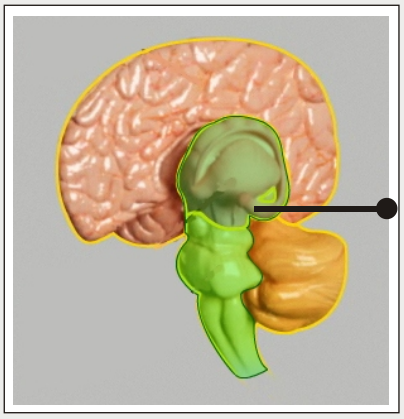

Brainstem

(Fig.3)

Hindbrain:

The hindbrain includes the upper portion of the spinal cord, the brain stem and the cerebellum. The hindbrain controls the body's vital functions such as respiration and heart rate.

The cerebellum coordinates movement and is involved in learned rote movements when you play the piano or hit a tennis ball you are activating the cerebellum.

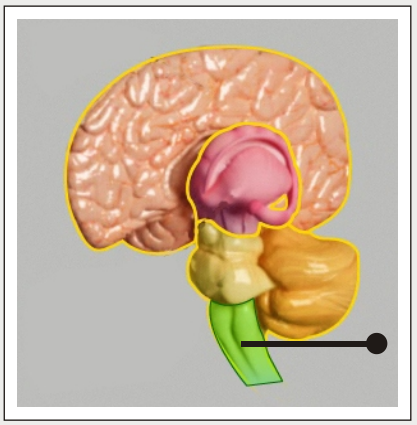

Spinal Cord
(Fig.4)

Lobes of the Brain

Each cerebral hemisphere can be divided into sections, or lobes, each of which specializes in different functions.

To understand each lobe and its specialty we will take a tour of the cerebral hemispheres, starting with the two frontal lobes, which lie directly behind the forehead.

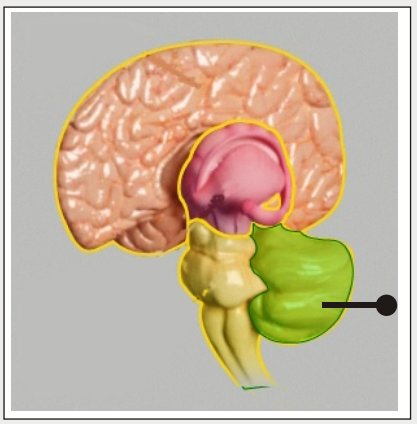

Cerebellum

(Fig.5)

Frontal Lobe:

When you plan a schedule, imagine the future, or use reasoned arguments, these two lobes do much of the work. One of the ways the frontal lobes seem to do these things is by acting as short-term storage sites, allowing one idea to be kept in mind while other ideas are considered.

(Refer fig.6)

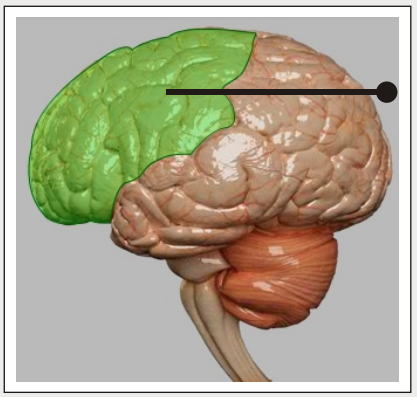

Frontal Lobe

(Fig.6)

In the rearmost portion of each frontal lobe is a motor area, which helps control voluntary movement. A nearby place on the left frontal lobe called Broca's area allows thoughts to be transformed into words.

Parietal Lobe:

When you enjoy a good meal—the taste, aroma, and texture of the food—two sections behind the frontal lobes called the parietal lobes are at work. The forward parts of these lobes, just behind the motor areas, are the primary sensory areas.

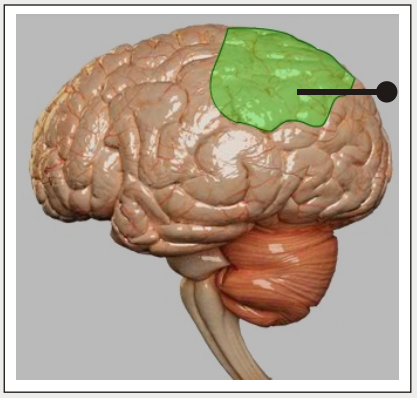

Parietal Lobe

(Fig.7)

These areas receive information about temperature, taste, touch, and movement from the rest of the body. Reading and arithmetic are also functions in the repertoire of each parietal lobe.

(Refer fig.7)

Occipital Lobe:

As you look at the words and pictures on this page, two areas at the back of the brain are at work. These lobes are called the occipital lobes.

They function to process images from the eyes and link that information with images stored in memory. Damage to the occipital lobes can cause blindness.

(Refer fig.8)

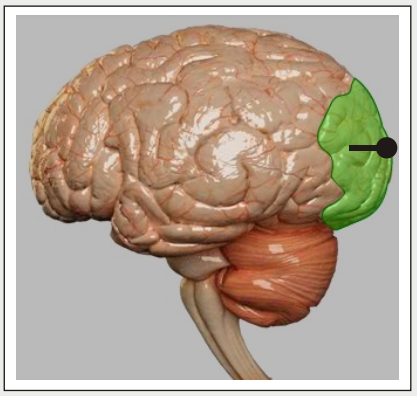

Occipital Lobe

(Fig.8)

Temporal Lobe:

These lobes lie in front of the visual areas and nest under the parietal and frontal lobes. Whether you appreciate symphonies or rock music, your brain responds through the activity of these lobes.

At the top of each temporal lobe is an area responsible for receiving information from the ears.

Temporal Lobe

(Fig.9)

The underside of each temporal lobe plays a crucial role in forming and retrieving memories, including those associated with music. Other parts of this lobe seem to integrate memories and sensations of taste, sound, sight, and touch.

(Refer fig.9)

Cerebrum

When people see pictures of the brain it is usually the cerebrum that they notice. The cerebrum sits at the topmost part of the brain and is the source of intellectual activities.

It holds your memories, allows you to plan, enables you to imagine and think. It allows you to recognize friends, read books, and play games.

(Refer fig.10)

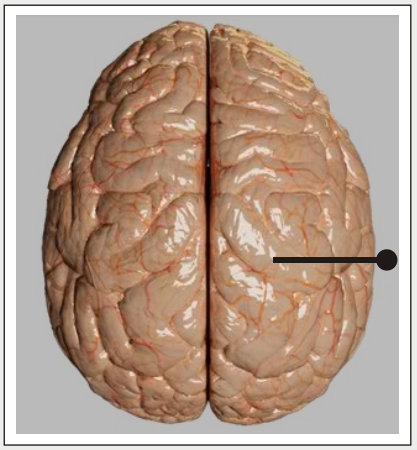

Cerebrum

(Fig.10)

The cerebrum is split into two halves (hemispheres) by a deep fissure. Despite the split, the two cerebral hemispheres communicate with each other through a thick tract of nerve fibers that lies at the base of this fissure. Although the two hemispheres seem to be mirror images of each other, they are different.

For instance, the ability to form words seems to lie primarily in the left hemisphere, while the right hemisphere seems to control many abstract reasoning skills.

For some as-yet-unknown reason, nearly all of the signals from the brain to the body and vice-versa cross over on their way to and from the brain. This means that the right cerebral hemisphere primarily controls the left side of the body and the left hemisphere primarily controls the right side. When one side of the brain is damaged, the opposite side of the body is affected. For example, a stroke in the right hemisphere of the brain can leave the left arm and leg paralyzed.

The Cerebral Cortex

Coating the surface of the cerebrum and the cerebellum is a vital layer of tissue the thickness of a stack of two or three dimes. It is called the cortex, from the Latin word for bark.

Most of the actual information processing in the brain takes place in the cerebral cortex. When people talk about "gray matter" in the brain they are talking about this thin rind.

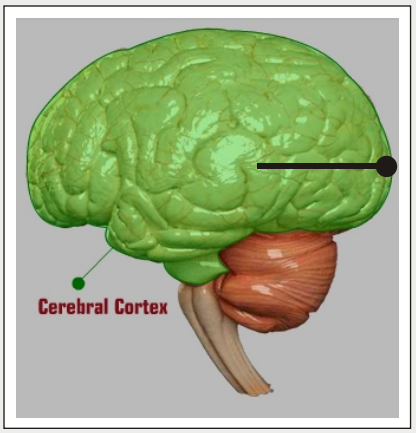

The Cerebral Cortex

(Fig.11)

The cortex is gray because nerves in this area lack the insulation that makes most other parts of the brain appear to be white. The folds in the brain add to its surface area and therefore increase the amount of gray matter and the quantity of information that can be processed.

(Refer fig.11)

Inner Brain Structures

Deep within the brain lie structures that are the gatekeepers between the spinal cord and the cerebral hemispheres. These structures not only determine our emotional state, they also modify our perceptions and responses depending on that state, and allow us to initiate movements that you make without thinking about them.

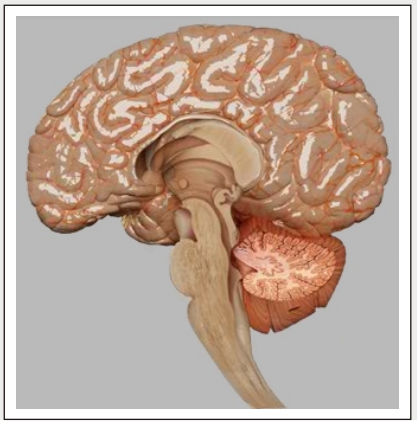

(Fig.12)

Like the lobes in the cerebral hemispheres, the structures described below come in pairs: each is duplicated in the opposite half of the brain.

(Refer fig.12)

Hypothalamus:

The hypothalamus is about the size of a pearl and directs a multitude of important functions. It wakes you up in the morning, and gets the adrenaline flowing during a

The hypothalamus is also an important emotional center, controlling the molecules that make you feel exhilarated, angry, or unhappy.

(Refer fig.13)

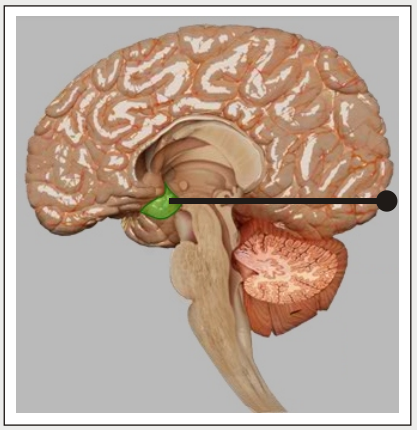

Hypothalamus

(Fig.13)

Thalamus:

Near the hypothalamus lies the thalamus, a major clearinghouse for information going to and from the spinal cord and the cerebrum.

(Refer fig.14)

Thalamus

(Fig.14)

Hippocampus:

An arching tract of nerve cells leads from the hypothalamus and the thalamus to the hippocampus.

This tiny nub acts as a memory indexer—sending memories out to the appropriate part of the cerebral hemisphere for long-term storage and retrieving them when necessary.

(Refer fig.15)

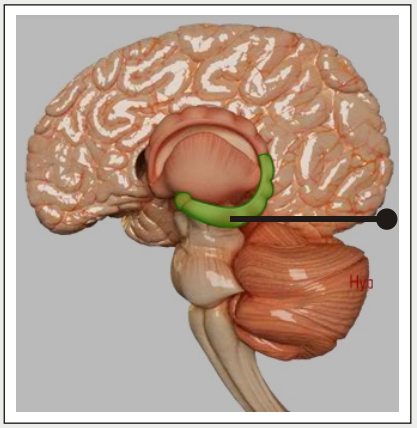

Hippocampus

(Fig.15)

Basal Ganglia:

The basal ganglia are clusters of nerve cells surrounding the thalamus. They are responsible for initiating and integrating movements.

Parkinson's disease, which results in tremors, rigidity, and a stiff, shuffling walk, is a disease of nerve cells that lead into the basal ganglia.

(Refer fig.16)

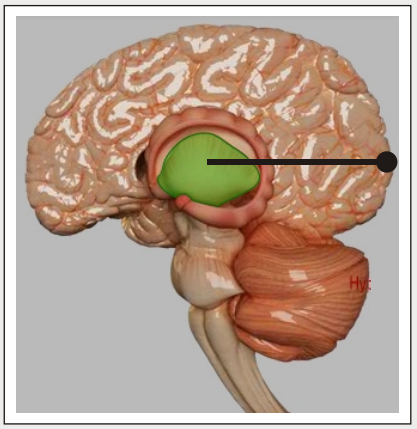

Basal Ganglia

(Fig.16)

What is Hydrocephalus?

The term hydrocephalus is derived from the Greek words "hydro" meaning water and "cephalus" meaning head. As the name implies, it is a condition in which the primary characteristic is excessive accumulation of fluid in the brain. Although hydrocephalus was once known as "water on the brain," the "water" is actually cerebrospinal fluid (CSF) — a clear fluid that surrounds the brain and spinal cord. The excessive accumulation of CSF results in an abnormal widening of spaces in the brain called ventricles. Ventricles are hollow cavities within the brain that are constantly producing CSF. This widening creates potentially harmful pressure on the tissues of the brain.

The ventricular system is made up of four ventricles connected by narrow passages. Normally, CSF flows through the ventricles, exits into cisterns (closed spaces that serve as reservoirs) at the base of the brain, bathes the surfaces of the brain and spinal cord, and then reabsorbs into the bloodstream.

CSF has three important life-sustaining functions:

- To keep the brain tissue buoyant, acting as a cushion or "shock absorber"
- To act as the vehicle for delivering nutrients to the brain and removing waste; and
- To flow between the cranium and spine and compensate for changes in intracranial blood volume (the amount of blood within the brain).

The balance between production and absorption of CSF is critically important. Because CSF is made continuously, medical conditions that block its normal flow or absorption will result in an over-accumulation of CSF. The resulting pressure of the fluid against brain tissue is what causes hydrocephalus.

Types of Hydrocephalus

Hydrocephalus may be congenital or acquired.

Congenital hydrocephalus:

Congenital hydrocephalus is present at birth and may be caused by either events or influences that occur during fetal development, or genetic abnormalities.

Acquired hydrocephalus:

Acquired hydrocephalus develops at the time of birth or at some point afterward. This type of hydrocephalus can affect individuals of all ages and may be caused by injury or disease.

Hydrocephalus may also be communicating or non-communicating.

Communicating hydrocephalus:

Communicating hydrocephalus occurs when the flow of CSF is blocked after it exits the ventricles. This form is called communicating because the CSF can still flow between the ventricles, which remain open.

Non-communicating hydrocephalus:

Non-communicating hydrocephalus - also called "obstructive" hydrocephalus - occurs when the flow of CSF is blocked along one or more of the narrow passages connecting the ventricles. One of the most common causes of hydrocephalus is "aqueductal stenosis." In this case, hydrocephalus results from a narrowing of the aqueduct of Sylvius, a small passage between the third and fourth ventricles in the middle of the brain.

There are two other forms of hydrocephalus which do not fit exactly into the categories mentioned above and primarily affect adults: hydrocephalus ex-vacuo and normal pressure hydrocephalus.

Hydrocephalus ex-vacuo:

Hydrocephalus ex-vacuo occurs when stroke or traumatic injury cause damage to the brain. In these cases, brain tissue may actually shrink.

Normal pressure hydrocephalus:

Normal pressure hydrocephalus can happen to people at any age, but it is most common among the elderly. It may result from a subarachnoid hemorrhage, head trauma, infection, tumor, or complications of surgery. However, many people develop normal pressure hydrocephalus even when none of these factors are present for reasons that are unknown.

Symptoms of Hydrocephalus

Symptoms of hydrocephalus vary with age, disease progression, and individual differences in tolerance to the condition. For example, an infant's ability to compensate for increased CSF pressure and enlargement of the ventricles differs from an adult's. The infant skull can expand to accommodate the buildup of CSF because the sutures (the fibrous joints that connect the bones of the skull) have not yet closed.

In infancy, the most obvious indication of hydrocephalus is often a rapid increase in head circumference or an unusually large head size. Other symptoms may include:

- Vomiting
- Sleepiness
- Irritability
- Downward deviation of the eyes (also called "sunsetting"), and
- Seizures

Older children and adults may experience different symptoms because their skulls cannot expand to accommodate the buildup of CSF.

Symptoms may include:

- Blurred or double vision
- Sunsetting of the eyes
- Urinary incontinence
- Lethargy, drowsiness
- Headache followed by vomiting and nausea
- Slowing or loss of developmental progress
- Irritability or other changes in personality
- Changes in cognition including memory loss
- Problems with balance, poor coordination, gait disturbance
- Papilledema (swelling of the optic disk which is part of the optic nerve)

Symptoms of normal pressure hydrocephalus include:

- Problems with walking
- Impaired bladder control leading to urinary frequency and/or incontinence
- Progressive mental impairment and dementia
- Lethargy, drowsiness
- An individual with this type of hydrocephalus may have a general slowing of movements or may complain that his or her feet feel "stuck.

Because some of these symptoms may also be experienced in other disorders such as Alzheimer's disease, Parkinson's disease, and Creutzfeldt-Jakob disease, normal pressure hydrocephalus is often incorrectly diagnosed and treated. Doctors may use a variety of tests, including brain scans (CT and/or MRI), a spinal tap or lumbar catheter, intracranial pressure monitoring, and neuropsychological tests, to help them accurately diagnose normal pressure hydrocephalus and rule out any other conditions.

The symptoms described in this section account for the most typical ways in which progressive hydrocephalus manifests itself, but it is important to remember that symptoms vary significantly from one person to the next.

Causes of Hydrocephalus

The causes of hydrocephalus are still not well understood.

Hydrocephalus may result from the following:

- Inherited genetic abnormalities (such as the genetic defect that causes aqueductal stenosis)
- Developmental disorders (such as those associated with neural tube defects including spina bifida and encephalocele).
- Complications of premature birth such as intraventricular hemorrhage
- Meningitis
- Tumors
- Traumatic head injury, or
- Subarachnoid hemorrhage

Diagnosis

Your physician will perform the following:

- Physical exam with emphasis on neurological evaluation
- Medical History

Your physician selects the appropriate diagnostic tool based on the patient's age, clinical presentation, and the presence of known or suspected abnormalities of the brain or spinal cord. Diagnostic testing that may be ordered can include:

MRI:

A large machine with a strong magnet linked to a computer is used to make detailed pictures of areas inside your head. Sometimes a special dye (contrast material) is injected into a blood vessel in your arm or hand to help show differences in the tissues of the brain. The pictures

CT scan:

An x-ray machine linked to a computer takes a series of detailed pictures of your head. You may receive contrast material by injection into a blood vessel in your arm or hand. The contrast material makes abnormal areas easier to see.

Ultrasonography:

A non-invasive test using sound waves to create computer images of soft structures.

Treatment Overview

Hydrocephalus is most often treated by surgically inserting a shunt system. This shunt system diverts the flow of CSF from the brain and spinal cord to another area of the body where it can be absorbed as part of the normal circulatory process.

A shunt system consists of the shunt, a flexible but sturdy plastic tube, a catheter, and a valve. One end of the catheter is placed within a ventricle inside the brain or in the CSF outside the spinal cord. The other end of the catheter is commonly placed within the abdominal cavity, but may be placed at other sites in the body depending on the patient's situation. A valve located along the catheter maintains one-way flow and regulates the rate of CSF flow. Shunt systems may be permanent or temporary and may need to be replaced if they malfunction.

Your neurosurgeon will discuss all options available for your particular condition. This learning module will explain the most common procedure: Ventriculoperitoneal (VP) Shunt Surgery.

Surgical Treatment

Ventriculoperitoneal Shunt surgery is performed by a neurosurgeon in the hospital operating room with the patient under general anesthesia. Your hair will be shaved over the area where the incision will be made in the scalp.

Your surgeon makes a small incision in your scalp usually behind the ear.

A drill is then used to place a small hole in the skull bone so the surgeon can access the brain tissues.

(Refer fig. "17,18 & 19")

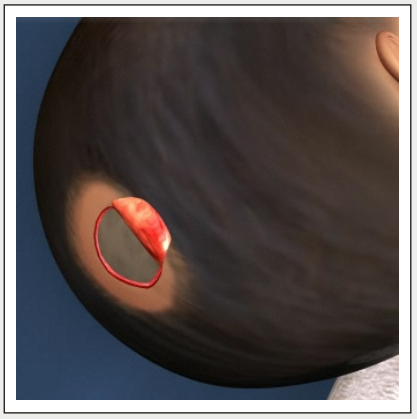

(Fig.17)

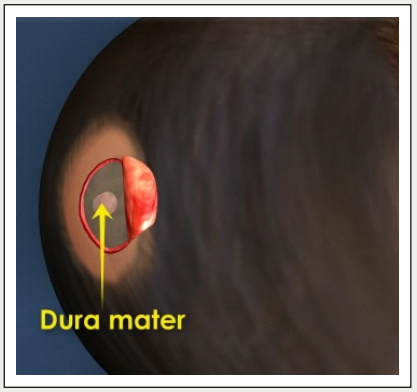

(Fig.18)

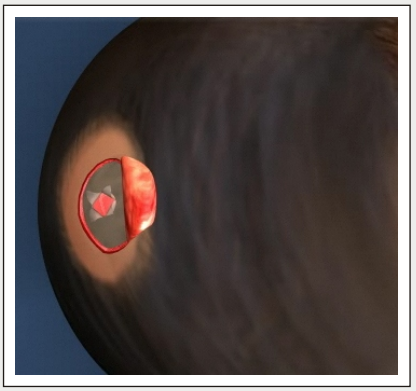

(Fig.19)

A catheter is inserted through the hole and into the ventricles.

Your surgeon then tunnels another catheter under the skin from the head down the neck and into the peritoneal cavity of the abdomen.

Small incisions may be made in the neck and abdomen to assist with the tunneling of the catheter.

(Refer fig. "20 &21")

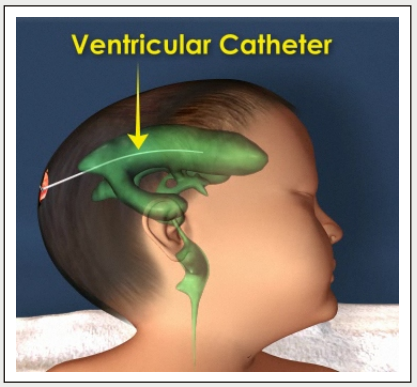

(Fig.20)

(Fig.21)

The valve portion of the shunt system is placed under the skin behind the ear.

Both catheters are then attached to the valve which controls the flow of CSF.

The incisions are closed with sutures or staples and covered with sterile dressings.

(Refer fig. "22 & 23")

(Fig.22)

(Fig.23)

Post Operative Guidelines

After surgery your surgeon will give you guidelines to follow to ensure a good outcome.

Common post-operative guidelines following ventriculoperitoneal shunt surgery include:

- You will be transferred to the recovery room after surgery for monitoring.
- You will be given pain medications to keep you comfortable and antibiotics to prevent infection.
- Keep the incisions clean and dry. You may shower once the stitches and/or staples are removed unless otherwise directed by your surgeon.
- Do not scratch the incision areas as this can lead to infection.
- If the incision areas become red, painful or draining, call your surgeon as these are signs of infection.
- If you experience headache, vomiting, visual problems, confusion, fever, or increased lethargy, call your surgeon right away.
- It is important to keep all your post operative appointments with your surgeon to ensure a good outcome.
- Eating a healthy diet and not smoking will promote healing.

Risks and Complications

As with any major surgery there are potential risks involved. The decision to proceed with the surgery is made because the advantages of surgery outweigh the potential disadvantages. It is important that you are informed of these risks before the surgery takes place.

Complications can be medical (general) or specific to Ventriculoperitoneal Shunt surgery.

Medical complications include those of the anesthetic and your general well being. Almost any medical condition can occur so this list is not complete. Complications include:

- Allergic reactions to medications
- Blood loss requiring transfusion with its low risk of disease transmission
- Heart attacks, strokes, kidney failure, pneumonia, bladder infections
- Complications from nerve blocks such as infection or nerve damage
- Serious medical problems can lead to ongoing health concerns, prolonged hospitalization, or rarely death.

Complications are rare after VP shunt surgery, but unexpected events can follow any operation. Your surgeon feels that you should be aware of complications that may take place so that your decision to proceed with this operation is taken with all relevant information available to you.

Specific complications of VP shunt surgery can include:

- Infection requiring removal of shunt and reinsertion of new shunt
- Bleeding in the brain
- Damage to brain tissues
- Mechanical failure of the shunt requiring new surgery
- Obstruction of the shunt requiring revision surgery
- Need to lengthen or replace the catheter

Some complications can lead to other problems such as overdraining or underdraining.

- Overdraining occurs when the shunt allows CSF to drain from the ventricles more quickly than it is produced. Overdraining can cause the ventricles to collapse, tearing blood vessels and causing headache, hemorrhage (subdural hematoma), or slit-like ventricles (slit ventricle syndrome).
- Underdraining occurs when CSF is not removed quickly enough and the symptoms of hydrocephalus recur.

When there is reason to suspect that a shunt system is not functioning properly (for example, if the symptoms of hydrocephalus return), medical attention should be sought immediately.

Risk factors that can negatively affect adequate healing after surgery include:

(Fig. 24)

Disclaimer

A good knowledge of this procedure will make the stress of undertaking the procedure easier for you to bear. The decision to proceed with the procedure is made because the advantages of the procedure outweigh the potential disadvantages. It is important that you are informed of these risks before the procedure.

☐ ☐ ☐ **YOUR SURGERY DATE**

☐ **READ YOUR BOOK AND MATERIAL**

☐ **VIEW YOUR VIDEO /CD / DVD / WEBSITE**

☐ **PRE - HABILITATION**

☐ **ARRANGE FOR BLOOD**

☐ **MEDICAL CHECK UP**

☐ **ADVANCE MEDICAL DIRECTIVE**

☐ **PRE - ADMISSION TESTING**

☐ **FAMILY SUPPORT REVIEW**

Physician's Name : _____

Physician's Signature: _____

Date : _____

Patient's Name : _____

Patient's Signature: _____

Date : _____