



GHADIALI

General Surgery

P R E S E N T S

Dr. Mufa T. Ghadiali is skilled in all aspects of General Surgery.
His General Surgery Services include:

- General Surgery
- Advanced Laparoscopic Surgery
- Surgical Oncology
- Gastrointestinal Surgery
- Hernia Surgery
- Endoscopy

Anatomy Of The Foot And Ankle

Multimedia Health Education

Disclaimer

This movie is an educational resource only and should not be used to manage Orthopaedic Health. All decisions about management of the Foot and Ankle must be made in conjunction with your Physician or a licensed healthcare provider.

Mufa T. Ghadiali, M.D., F.A.C.S

Diplomate of American Board of Surgery

6405 North Federal Hwy., Suite 402
Fort Lauderdale, FL 33308

Tel: 954-771-8888

Fax: 954- 491-9485

www.ghadialisurgery.com

GHADIALI

MULTIMEDIA HEALTH EDUCATION MANUAL

TABLE OF CONTENTS

SECTION	CONTENT
1 . ANATOMY	
a. Ankle & Foot Anatomy	
b. Soft Tissue Anatomy	
2 . BIOMECHANICS	

Introduction

The foot and ankle in the human body work together to provide balance, stability, movement, and Propulsion.

This complex anatomy consists of:

- 26 bones
- 33 joints
- Muscles
- Tendons
- Ligaments
- Blood vessels, nerves, and soft tissue

In order to understand conditions that affect the foot and ankle, it is important to understand the normal anatomy of the foot and ankle.

Ankle

The ankle consists of three bones attached by muscles, tendons, and ligaments that connect the foot to the leg. In the lower leg are two bones called the tibia (shin bone) and the fibula. These bones articulate (connect) to the Talus or ankle bone at the tibiotalar joint (ankle joint) allowing the foot to move up and down.

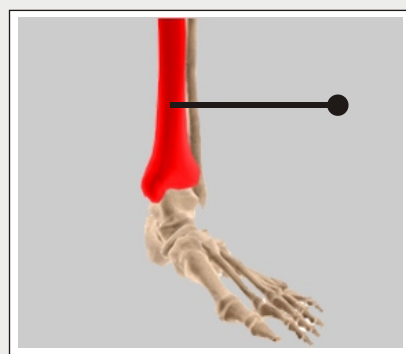
The bony protrusions that we can see and feel on the ankle are:

Lateral Malleolus: this is the outer ankle bone formed by the distal end of the fibula.

Medial Malleolus: this is the inner ankle bone formed by the distal end of the tibia.

Tibia (shin bone)

(Refer fig.1)

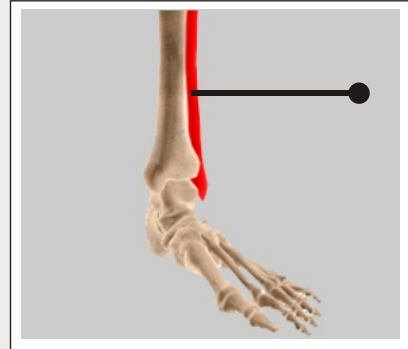


**Tibia
(shin bone)**

(Fig.1)

Fibula

(Refer fig.2)

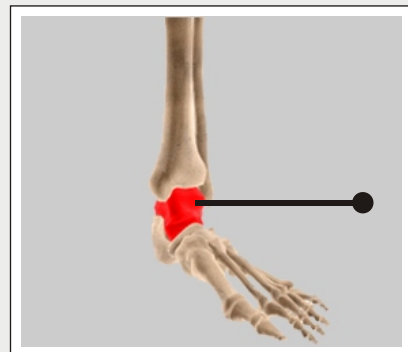


Fibula

(Fig.2)

Talus

(Refer fig.3)

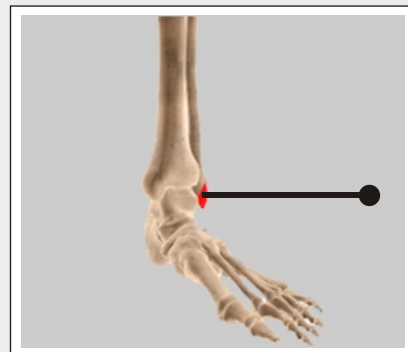


Talus

(Fig.3)

Lateral Malleolus

(Refer fig.4)

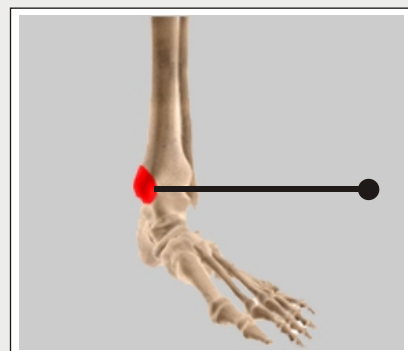


**Lateral
Malleolus**

(Fig.4)

Medial Malleolus

(Refer fig.5)



**Medial
Malleolus**

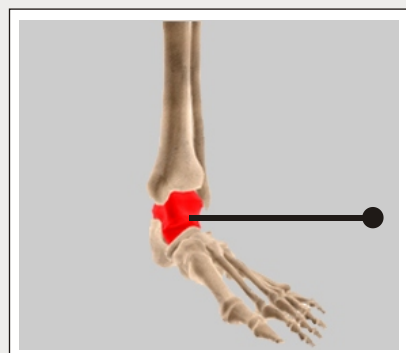
(Fig.5)

Hindfoot

The foot can be divided into three anatomical sections called the hindfoot, midfoot, and forefoot. The hindfoot consists of the Talus bone or ankle bone and the calcaneous bone or heel bone. The calcaneous bone is the largest bone in your foot while the talus bone is the highest bone in your foot. The calcaneous joins the Talus bone at the subtalar joint enabling the foot to rotate at the ankle. The hindfoot connects the midfoot to the ankle at the transverse tarsal joint.

Talus

(Refer fig.6)

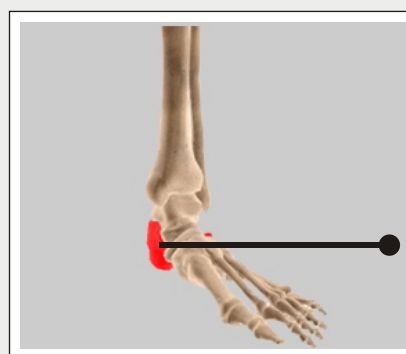


Talus

(Fig.6)

Calcaneus

(Refer fig.7)



Calcaneus

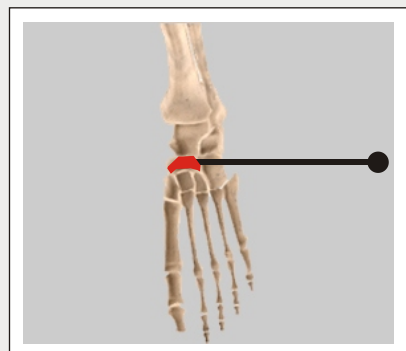
(Fig.7)

Midfoot

The midfoot contains five tarsal bones: the navicular bone, the cuboid bone, and 3 cuneiform bones. It connects the forefoot to the hindfoot with muscles and ligaments. The main ligament is the plantar fascia ligament. The midfoot is responsible for forming the arches of your feet and acts as a shock absorber when walking or running. The midfoot connects to the forefoot at the five tarsometatarsal joints.

Navicular

(Refer fig.8)

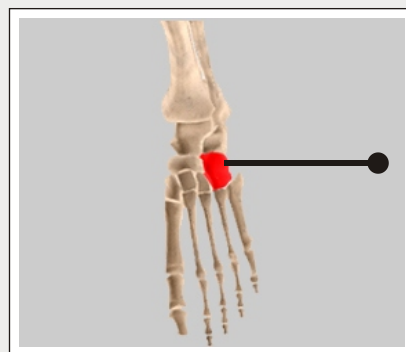


Navicular

(Fig.8)

Cuboid

(Refer fig.9)

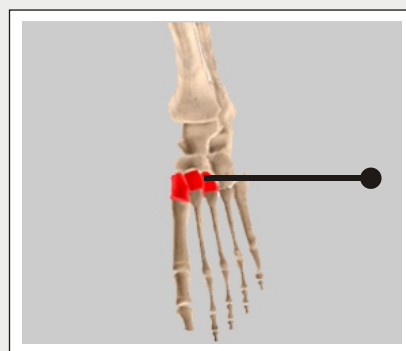


Cuboid

(Fig.9)

Cuneiform Bones

(Refer fig.10)



**Cuneiform
Bones**

(Fig.10)

Forefoot

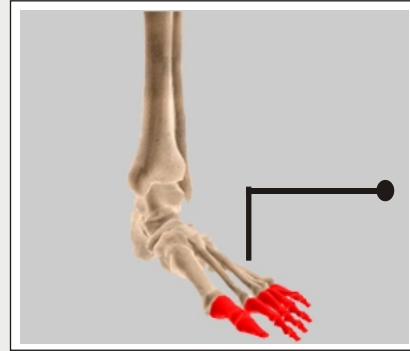
The forefoot consists of your toe bones, called phalanges, and metatarsal bones, the long bones in your feet. Phalanges connect to metatarsals at the ball of the foot by joints called phalange metatarsal joints.

Each toe has 3 phalange bones and 2 joints, while the big toe contains two phalange bones, two joints, and two tiny, round sesamoid bones that enable the toe to move up and down. Sesamoid bones are bones that develop inside of a tendon over a bony prominence.

The first metatarsal bone connected to the big toe is the shortest and thickest of the metatarsals and is the location for the attachment of several tendons. This bone is important for its role in propulsion and weight bearing.

Phalanges

(Refer fig.11)

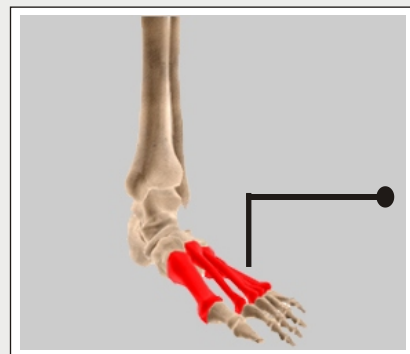


Phalanges

(Fig.11)

Metatarsal

(Refer fig.12)



Metatarsal

(Fig.12)

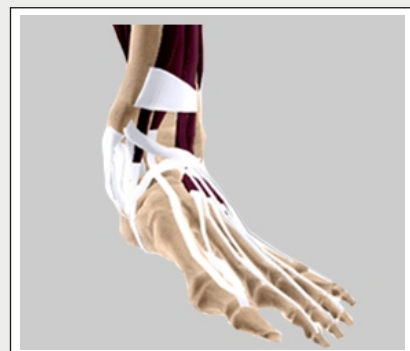Soft Tissue Anatomy

Our feet and ankle bones are held in place and supported by various soft tissues.

Cartilage

Shiny and smooth, cartilage allows smooth movement where two bones come in contact with each other.

(Refer fig.13)



Cartilage

(Fig.13)

Tendons

Tendons are soft tissue that connects muscles to bones to provide support. The Achilles tendon, also called the heel cord, is the largest and strongest tendon in the body. Located on the back of the lower leg it wraps around the calcaneus, or heel bone. When inflamed it causes a very painful condition called Achilles tendonitis and can make walking almost impossible due to the Pain.

(Refer fig.14)

Ligaments

Ligaments are strong rope like tissue that connects bones to other bones and help hold tendons in place providing stability to the joints. The plantar fascia is the longest ligament in the foot, originating at the calcaneus, heel bone, and continuing along the bottom surface of the foot to the forefoot.

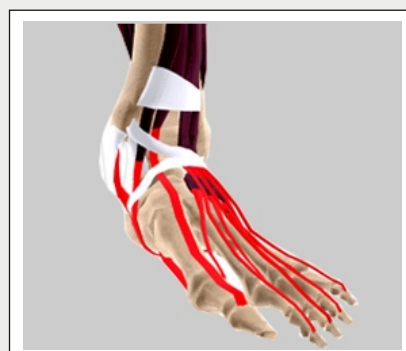It is responsible for the arches of the foot and provides shock absorption. A common cause of heel pain in adults, plantar fasciitis can occur when repetitive micro tears occur in the plantar fascia from overuse. Ankle sprains, the most commonly reported injury to the foot and ankle area, involve ligament strain, and usually occur to the talo-fibular ligament and the calcaneo-fibular ligament.

(Refer fig.15)

Muscles

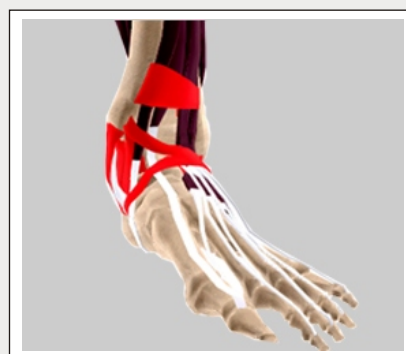Muscles are fibrous tissue capable of contracting to cause body movement. There are 20 muscles in the foot and these are classified as intrinsic or extrinsic. The intrinsic muscles are those located in the foot and are responsible for toe movement. The extrinsic muscles are located outside the foot in the lower leg.

(Refer fig.16)



Tendons

(Fig.14)



Ligaments

(Fig.15)

Unit 1:

Anatomy

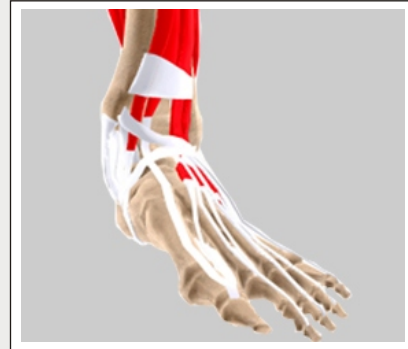The gastrocnemius or calf muscle is the largest of these and assists with movement of the foot. Muscle strains occur usually from overuse of the muscle in which the muscle is stretched without being properly warmed up.

(Refer fig.16)

Bursae

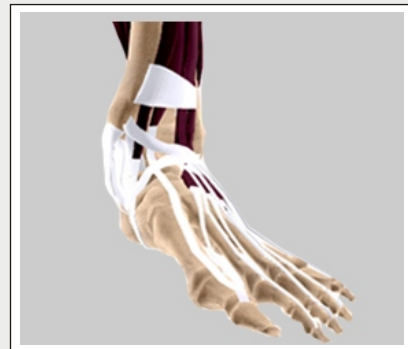Bursae are small fluid filled sacs that decrease friction between tendons and bone or skin. Bursae contain special cells called synovial cells that secrete a lubricating fluid. When this fluid becomes infected, a common painful condition known as Bursitis can develop.

(Refer fig.17)



Muscles

(Fig.16)



Bursae

(Fig.17)

Biomechanics of Foot & Ankle

Biomechanics is a term to describe movement of the body. The ankle joint by itself permits two movements:

Plantar flexion

Pointing the foot downward. This movement is normally accompanied by inversion of the foot.

(Refer fig.18)

Dorsiflexion

Raising the foot upward. This movement is normally accompanied by eversion of the foot. The foot (excluding the toes) also permits two movements:

(Refer fig.19)

Inversion

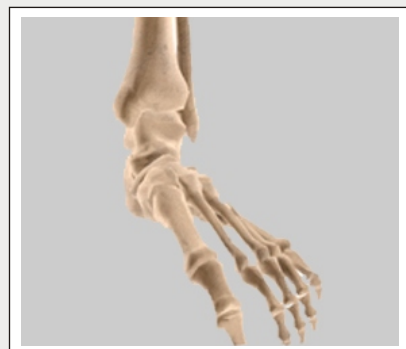Turning the sole of the foot inward.

(Refer fig.20)

Eversion

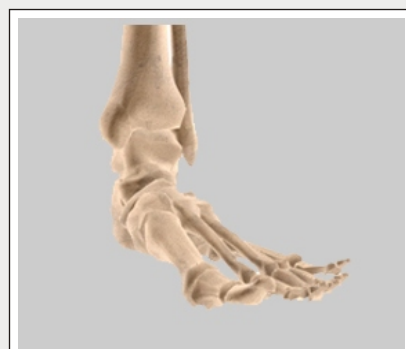Turning the sole of the foot outward.

(Refer fig.21)



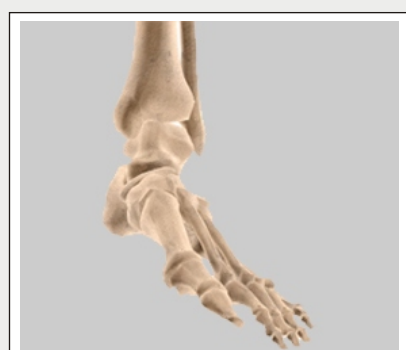Plantar flexion

(Fig.18)



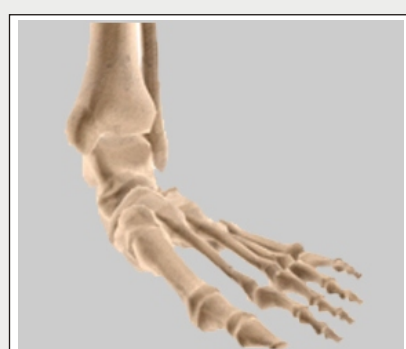Dorsiflexion

(Fig.19)



Inversion

(Fig.20)



Eversion

(Fig.21)

The toes allow four different movements:

Plantar flexion

Bending the toes towards the sole of the foot.

(Refer fig.22)

Dorsiflexion

Bending the toes towards the top of the foot.

(Refer fig.23)

Abduction

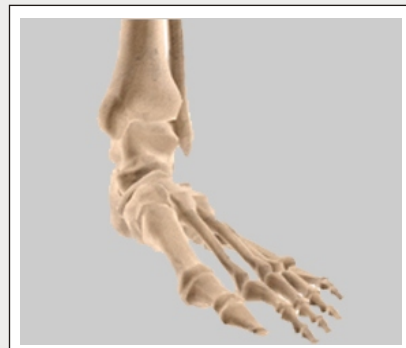Spreading the toes apart. This movement normally accompanies plantar dorsiflexion.

(Refer fig.24)

Adduction

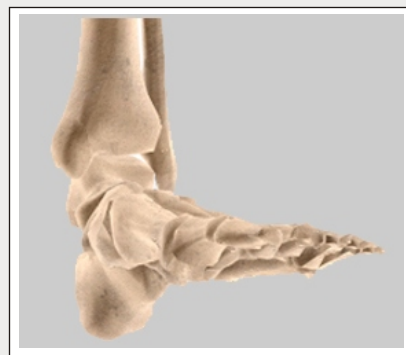Bringing the toes together. This movement normally accompanies plantar flexion.

(Refer fig.25)



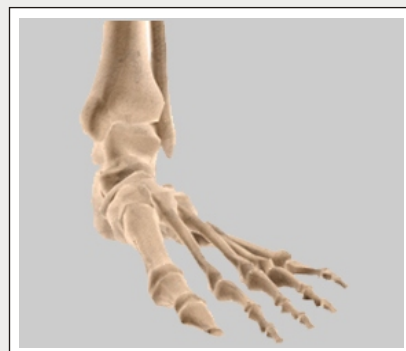Plantar flexion

(Fig.22)



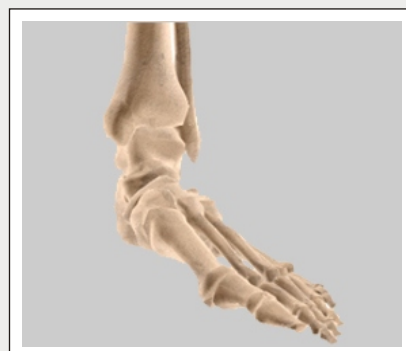Dorsiflexion

(Fig.23)



Abduction

(Fig.24)



Adduction

(Fig.25)

Disclaimer

This movie is an educational resource only and should not be used to manage Orthopaedic Health. All decisions about management of the Foot and Ankle must be made in conjunction with your Physician or a licensed healthcare provider

YOUR SURGERY DATE

READ YOUR BOOK AND MATERIAL

VIEW YOUR VIDEO /CD / DVD / WEBSITE

PRE - HABILITATION

ARRANGE FOR BLOOD

MEDICAL CHECK UP

ADVANCE MEDICAL DIRECTIVE

PRE - ADMISSION TESTING

FAMILY SUPPORT REVIEW

Physician's Name : _____

Patient's Name : _____

Physician's Signature: _____

Patient's Signature: _____

Date : _____

Date : _____