GHADIALI

GHADIALI
General Surgery

PRESENTS

Dr. Mufa T. Ghadiali is skilled in all aspects of General Surgery.
His General Surgery Services include:

- General Surgery
- Advanced Laparoscopic Surgery
- Surgical Oncology
- Gastrointestinal Surgery
- Hernia Surgery
- Endoscopy

Golfer's Elbow

Multimedia Health Education

Disclaimer

This movie is an educational resource only and should not be used to manage Orthopaedic Health. All decisions about Golfer's Elbow must be made in conjunction with your Physician or a licensed healthcare provider.

Mufa T. Ghadiali, M.D., F.A.C.S

Diplomate of American Board of Surgery

6405 North Federal Hwy., Suite 402
Fort Lauderdale, FL 33308

Tel.: 954-771-8888
Fax: 954- 491-9485

www.ghadialisurgery.com

MULTIMEDIA HEALTH EDUCATION MANUAL

TABLE OF CONTENTS

INTRODUCTION

Medial Epicondylitis, commonly referred to as Golfer's Elbow, is an overuse injury that causes inflammation of the tendons that attach to the bony prominence on the inside of the elbow. Despite its name, Golfer's Elbow occurs in non-golfers as well.

To learn more about Golfer's Elbow, it is important to understand the normal anatomy of the elbow in order to learn about diseases and conditions that can affect our elbow.

Introduction

The elbow in the human body consists of:

Bones

(Refer fig. 1)

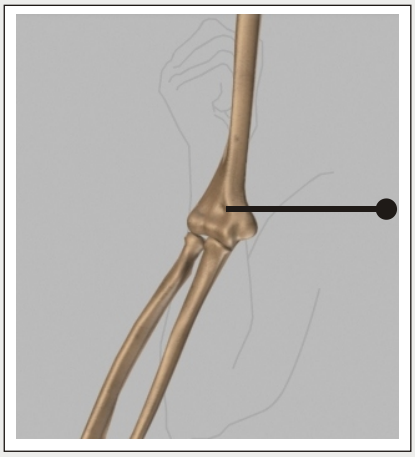

(Fig.1)

Joints

(Refer fig. 2)

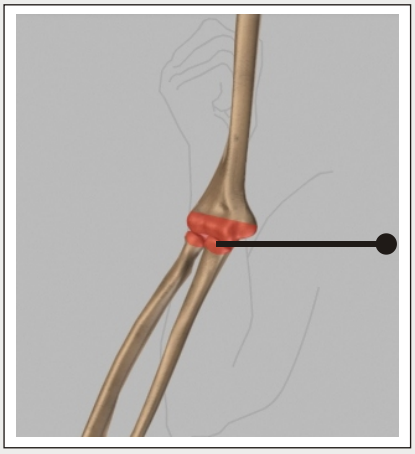

(Fig.2)

Muscles

(Refer fig. 3)

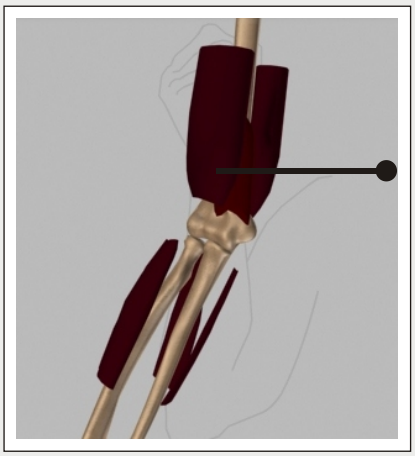

(Fig.3)

Ligaments and tendons

(Refer fig. 4)

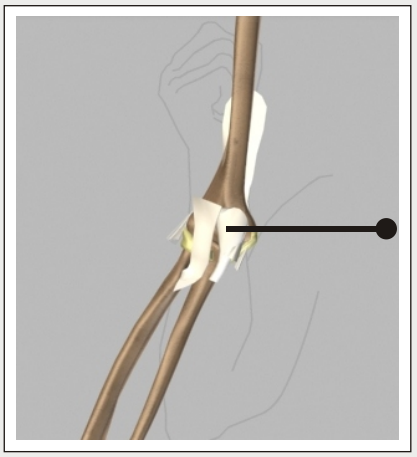

Ligaments and tendons

(Fig.4)

Numerous Blood vessels, nerves, and soft tissue

(Refer fig. 5)

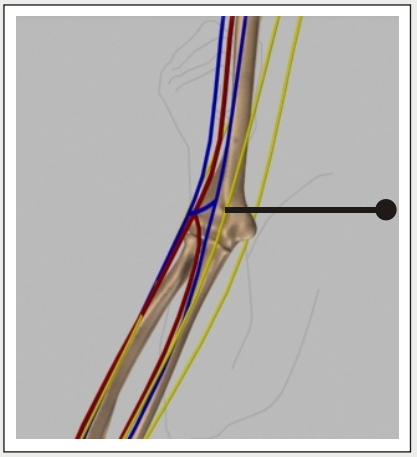

Numerous Blood vessels, nerves, and soft tissue

(Fig.5)

Normal Elbow Anatomy

The arm in the human body is made up of three bones that join together to form a hinge joint called the elbow. The upper arm bone or humerus connects from the shoulder to the elbow forming the top of the hinge joint.

The lower arm or forearm consists of two bones, the radius and the ulna. These bones connect the wrist to the elbow forming the bottom portion of the hinge joint.

(Refer fig. "6 to 9")

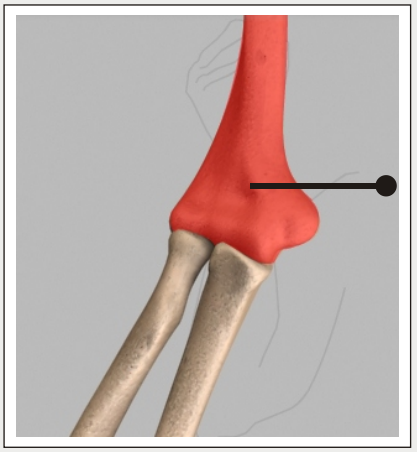

Humerus

(Fig.6)

The elbow joint is actually three separate joints surrounded by a watertight sac called a joint capsule. This capsule surrounds the elbow joint and contains lubricating fluid called synovial fluid.

- Humerus
- Ulna
- Radius
- Synovial fluid

(Refer fig. "6 to 9")

Ulna

(Refer fig. 7)

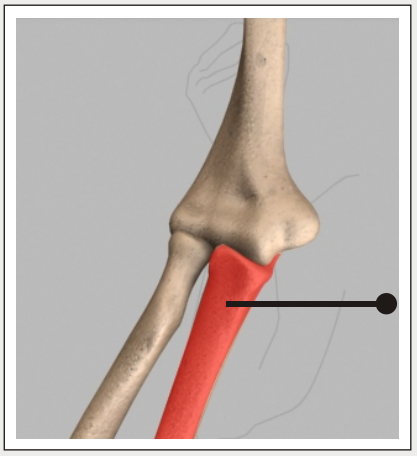

Ulna

(Fig.7)

Radius

(Refer fig. 8)

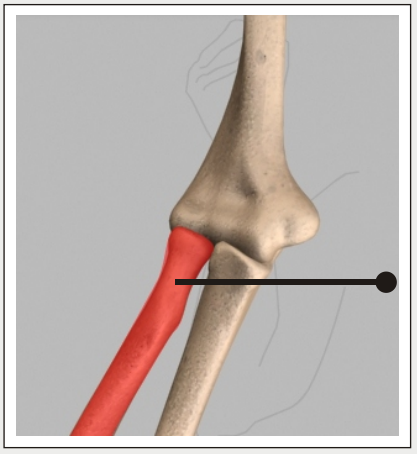

Radius

(Fig.8)

Synovial fluid

(Refer fig. 9)

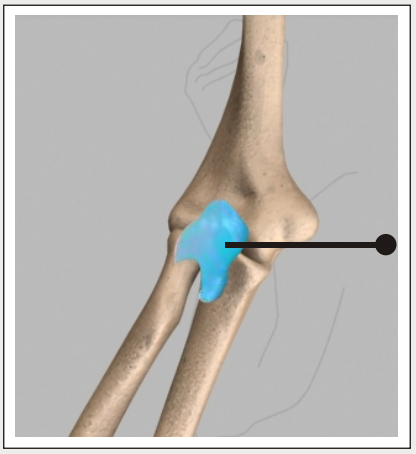

Synovial fluid

(Fig.9)

Normal Elbow Anatomy

The three joints of the elbow include:

- Ulnohumeral joint is where movement between the ulna and humerus occurs.
- Radiohumeral joint is where movement between the radius and humerus occurs.
- Proximal Radioulnar joint is where movement between the radius and ulna occurs.

(Refer fig. "10 to 12")

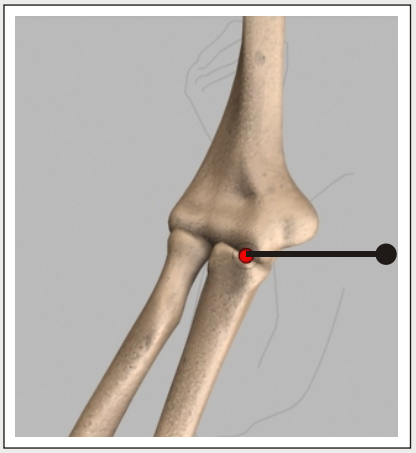

Ulnohumeral joint

(Fig.10)

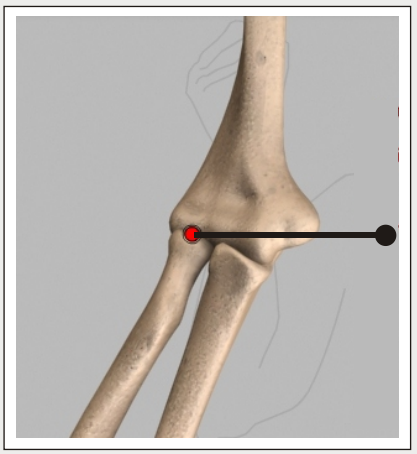

Radiohumeral joint

(Fig.11)

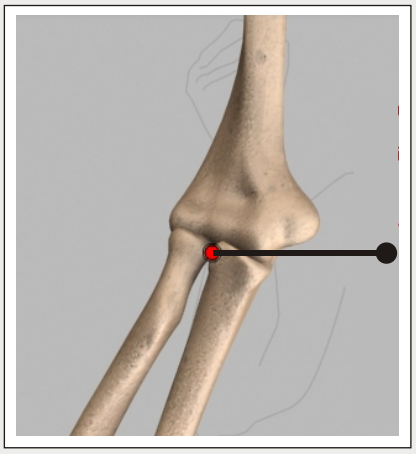

Proximal Radioulnar joint

(Fig.12)

Normal Elbow Anatomy

Our elbow is held in place and supported by various soft tissues. These include:

(Refer fig.13)

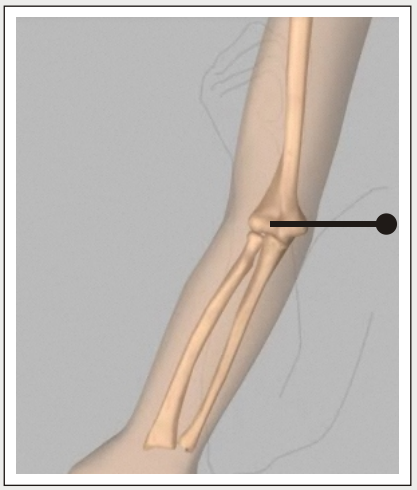

Normal Elbow Anatomy

(Fig.13)

Cartilage

Shiny and smooth, cartilage allows smooth movement where two bones come in contact with each other.

(Refer fig.14)

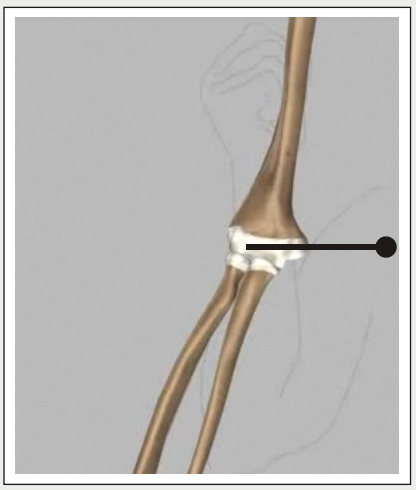

Cartilage

(Fig.14)

Tendons

Tendons are soft tissue that connects muscles to bones to provide support. The main tendons of the elbow include:

- Biceps tendon
- Triceps tendon
- Lateral Epicondyle
- Medial Epicondyle

(Refer fig.15 to 19)

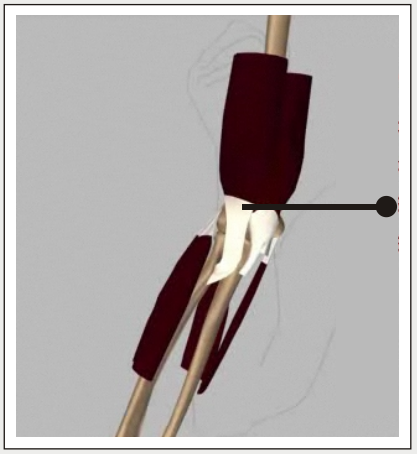

Tendons

(Fig.15)

Biceps tendon:

This tendon attaches the biceps muscle on the front of the arm to the radius allowing supination, rotation of the elbow.

(Refer fig.16)

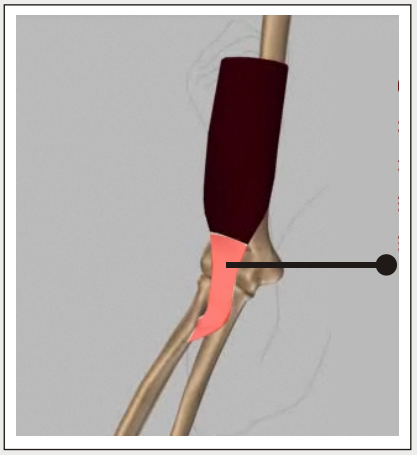

(Fig.16)

Triceps tendon:

This tendon attaches the triceps muscle on the back of the arm to the ulna bone allowing the elbow to straighten.

(Refer fig.17)

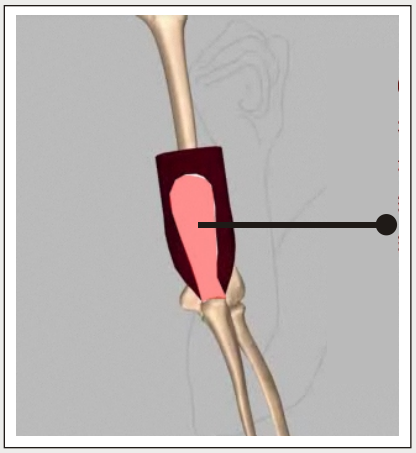

(Fig.17)

Lateral Epicondyle:

This bony prominence located just above the elbow on the outside is where the forearm muscles that straighten the fingers and wrist come together in one tendon to attach to the humerus.

It is this tendon that becomes inflamed in Tennis Elbow.

(Refer fig.18)

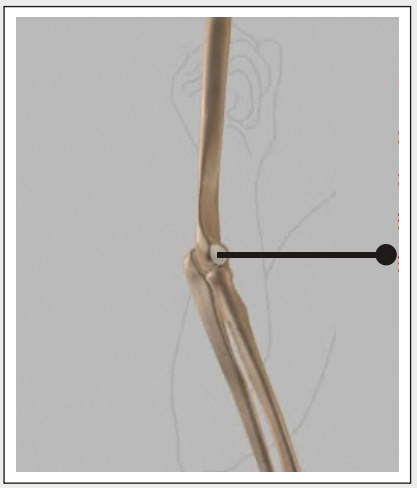

(Fig.18)

Medial Epicondyle:

This bony prominence located just above the elbow on the inside is where the muscles that bend the fingers and wrist come together in one tendon to attach to the humerus.

(Refer fig.19)

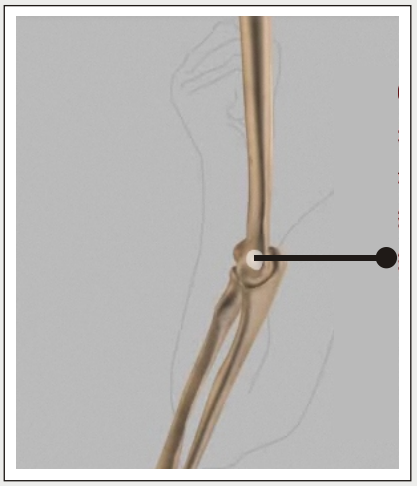

(Fig.19)

Ligaments

Ligaments are strong rope like tissue that connects bones to other bones and help hold tendons in place providing stability to joints. Ligaments around the elbow join to form a watertight sac called a joint capsule.

This capsule surrounds the elbow joint and contains lubricating fluid called synovial fluid. There are four main ligaments in the elbow:

(Refer fig.20)

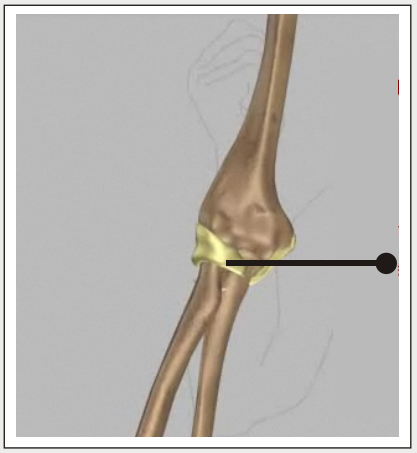

(Fig.20)

Medial collateral ligament:

Located on the inside of the elbow this ligament connects the ulna to the humerus.

(Refer fig.21)

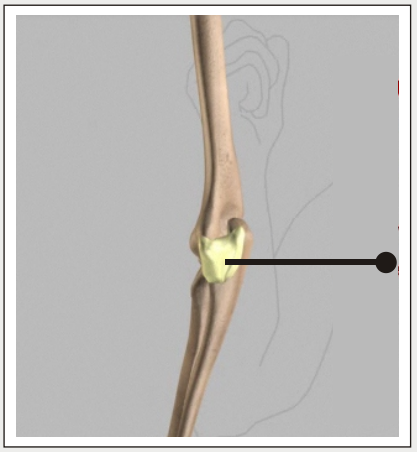

(Fig.21)

Lateral collateral ligament:

Located on the outside of the elbow this ligament connects the radius to the humerus.

(Refer fig.22)

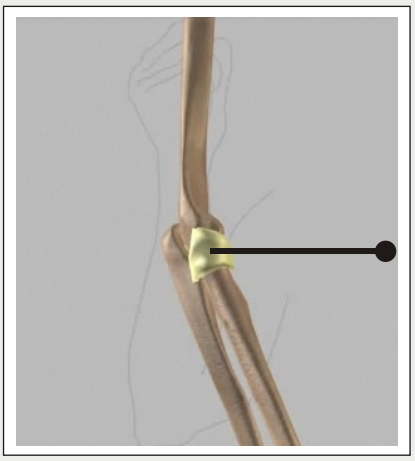

Lateral collateral ligament

(Fig.22)

Annular ligament:

This ligament forms a ring around the head of the radius bone, holding it tight against the ulna.

(Refer fig.23)

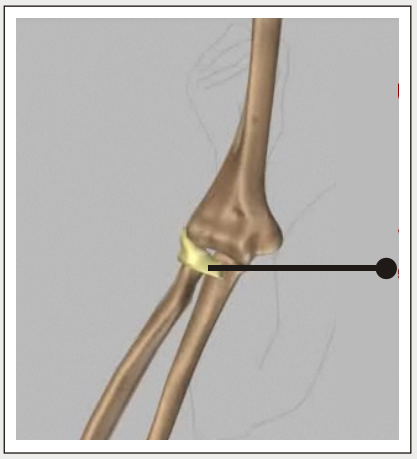

Annular ligament

(Fig.23)

Quadrate ligament:

This ligament also connects the radius to the ulna.

(Refer fig.24)

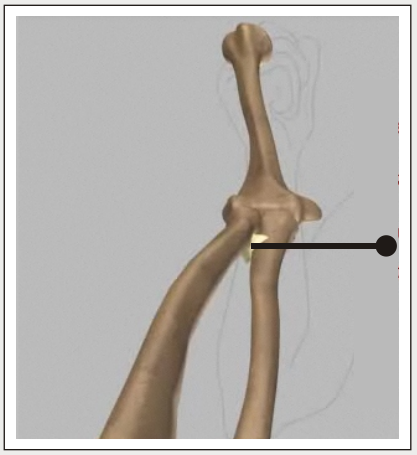

Quadrate ligament

(Fig.24)

Muscles

Muscles are fibrous tissue capable of contracting to cause body movement. The main muscles of the elbow include:

(Refer fig.25)

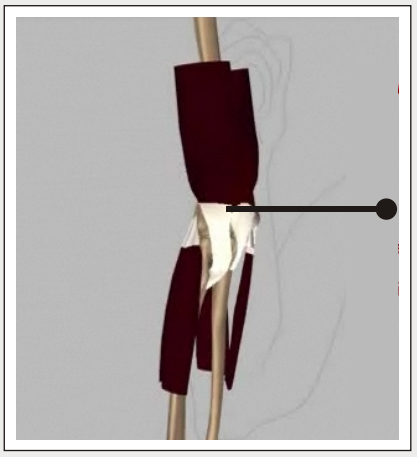

Muscles

(Fig.25)

Biceps:

This is the large muscle on the front of the arm above the elbow that allows elbow supination, rotation of the elbow

(Refer fig.26)

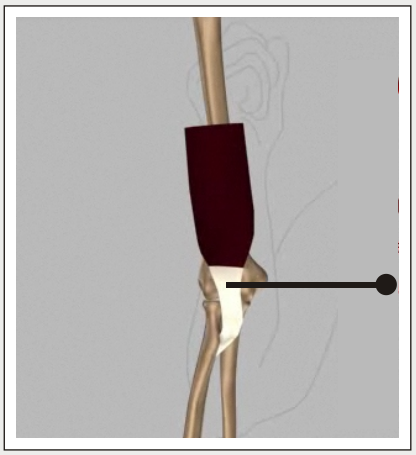

Biceps

(Fig.26)

Triceps:

This is the large muscle on the back of the arm above the elbow enabling elbow extension, straightening of the elbow.

(Refer fig.27)

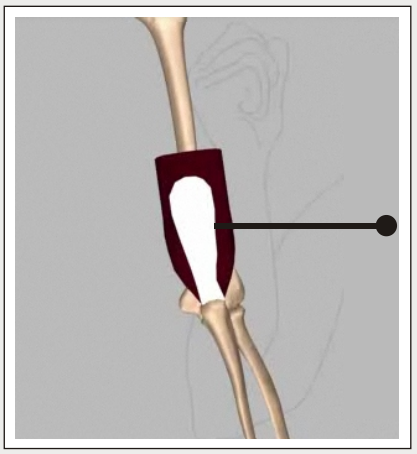

Triceps

(Fig.27)

Brachialis:

This muscle is the primary elbow flexor enabling bending of the elbow. It is located at the distal end of the humerus.

(Refer fig.28)

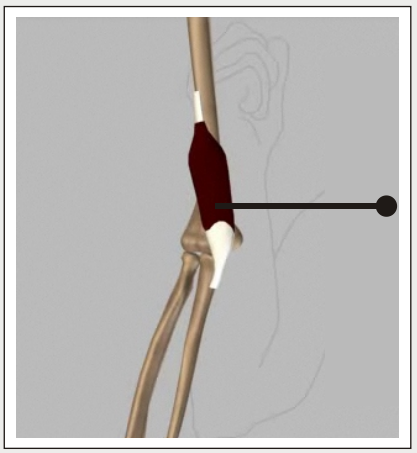

(Fig.28)

Wrist extensors:

These muscles of the forearm attach to the lateral epicondyle enabling extension of the hand and wrist.

(Refer fig.29)

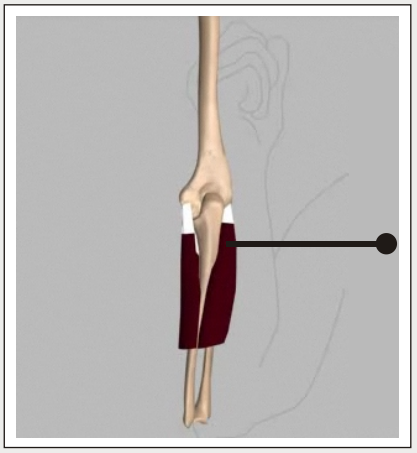

(Fig.29)

Wrist flexors:

These muscles of the forearm attach to the medial epicondyle enabling flexion of the hand and wrist.

(Refer fig.30)

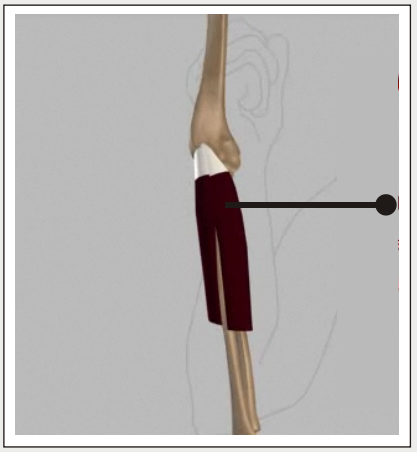

(Fig.30)

Nerves

Nerves are responsible for carrying signals back and forth from the brain to muscles in our body, enabling movement and sensation such as touch, pain, and hot or cold. The three main nerves of the arm are:

(Refer fig.31)

- Radial nerve
- Ulnar nerve
- Median nerve

(Refer fig. "32 to 34")

All three nerves begin at the shoulder and travel down the arm across the elbow.

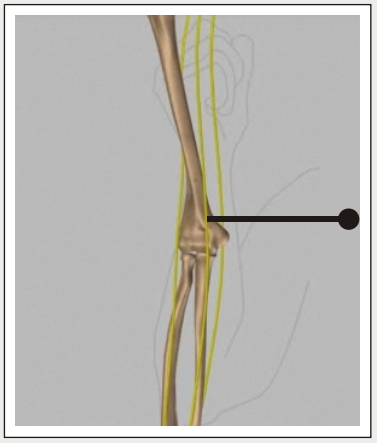

Nerves

(Fig.31)

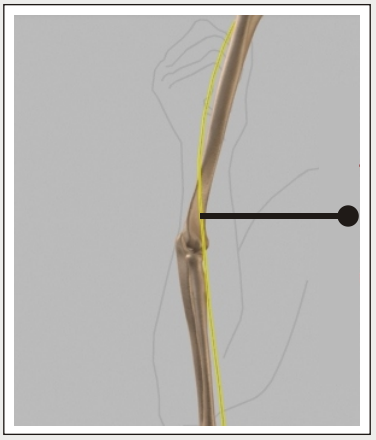

Radial nerve

(Fig.32)

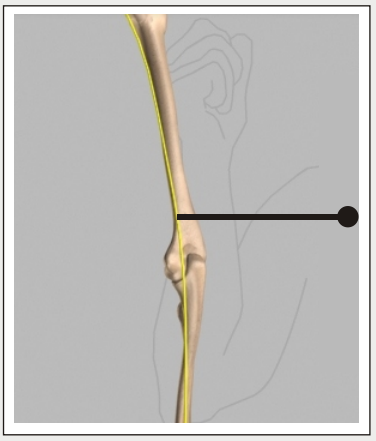

Ulnar nerve

(Fig.33)

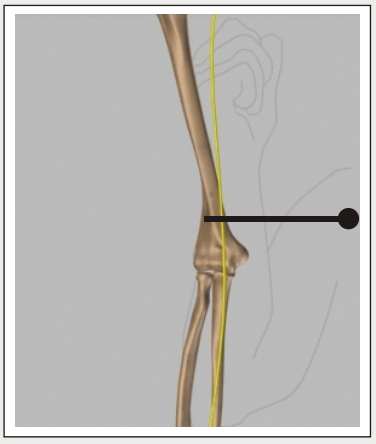

Median nerve

(Fig.34)

Blood Vessels

The main vessel of the arm is the brachial artery. This artery travels across the inside of the elbow at the bend and then splits into two branches below the elbow. These branches are:

(Refer fig.35)

Radial Artery:

The radial artery is the largest artery supplying the hand and wrist area. Traveling across the front of the wrist, nearest the thumb, it is this artery that is palpated when a pulse is counted at the wrist.

Ulnar Artery:

The ulnar artery travels next to the ulnar nerve through Guyon's canal in the wrist. It supplies blood flow to the front of the hand, fingers and thumb.

(Fig.35)

Bursae

Bursae are small fluid filled sacs that decrease friction between tendons and bone or skin. Bursae contain special cells called synovial cells that secrete a lubricating fluid. When this fluid becomes infected, a common painful condition known as Bursitis can develop

(Refer fig.36)

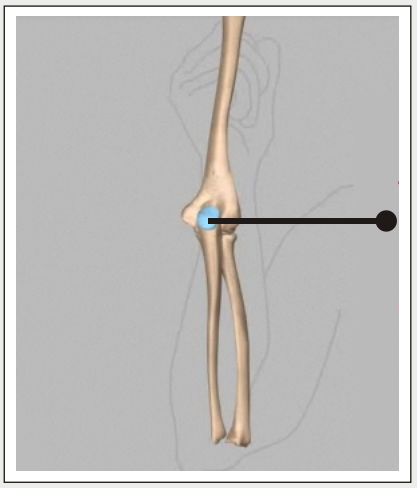

(Fig.36)

Biomechanics

Biomechanics is a term to describe movement of the body.

Flexion:

Bending the elbow (bringing the forearm towards the upper arm) occurs at the ulnohumeral and radiohumeral joints.

(Refer fig.37)

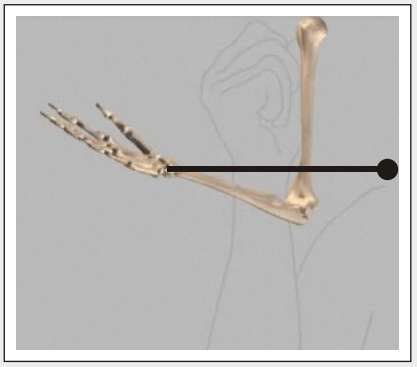

Flexion

(Fig.37)

Extension:

Straightening the elbow (bringing the forearm away from the upper arm) also occurs at the ulnohumeral and radiohumeral joints.

(Refer fig.38)

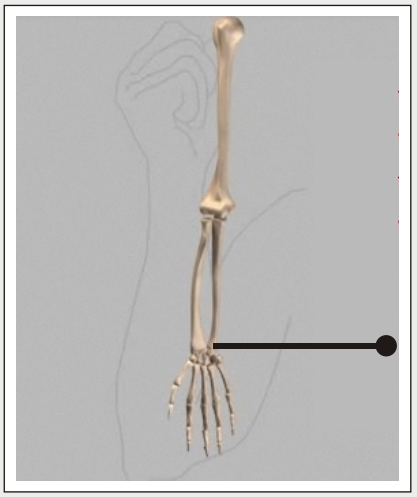

Extension

(Fig.38)

Pronation:

This movement is rotation of the forearm that moves the palm to a face down position.

It occurs at the articulation between the radius and ulna, the proximal radioulnar joint.

(Refer fig.39)

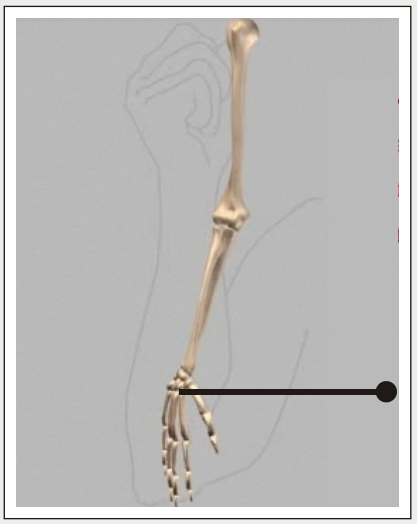

Pronation

(Fig.39)

Suppination:

This movement is rotation of the forearm so that the palm faces up. This also occurs at the proximal radioulnar joint.

(Refer fig.40)

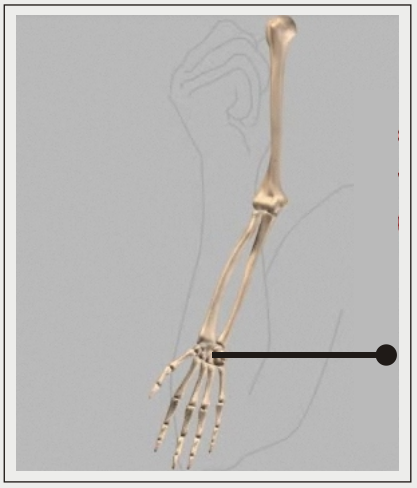

Suppination

(Fig.40)

What is Golfer's Elbow?

Golfer's elbow, also called Medial Epicondylitis, is a painful condition occurring from repeated muscle contractions in the forearm that leads to inflammation and micro-tears in the tendons that attach to the medial epicondyle. The medial epicondyle is the bony prominence that is felt on the inside of the elbow.

Golfer's elbow and Tennis Elbow are similar except that Golfer's elbow occurs on the inside of the elbow and Tennis Elbow occurs on the outside of the elbow. Both conditions are a type of Tendonitis which literally means "inflammation of the tendons".

Signs and symptoms

Signs and symptoms of Golfer's Elbow can include the following:

- Elbow pain that appears suddenly or gradually
- Achy pain to the inner side of the elbow during activity
- Elbow stiffness with decreased range of motion
- Pain may radiate to the inner forearm, hand or wrist
- Weakened grip
- Pain worsens with gripping objects
- Pain is exacerbated in the elbow when the wrist is flexed or bent forward toward the forearm.

Causes

Golfer's Elbow is usually caused by overuse of the forearm muscles and tendons that control wrist and finger movement but may also be caused by direct trauma such as with a fall, car accident, or work injury.

Golfer's elbow is commonly seen in golfer's, hence the name, especially when poor technique or unsuitable equipment is used when hitting the ball. Other common causes include any activity that requires repetitive motion of the forearm such as:

(Refer fig.41)

(Fig.41)

Golfer's Elbow

Diagnosis

Golfer's Elbow should be evaluated by an Orthopaedic specialist for proper diagnosis and treatment.

Your physician will perform the following:

- Medical History
- Physical Examination

Your physician may order an x-ray to rule out a fracture or arthritis as the cause of your pain.

Occasionally, if the diagnosis is unclear, your physician may order further tests to confirm Medical Epicondylitis.

X-rays:

A form of electromagnetic radiation that is used to take pictures of bones.

(Refer fig.42)

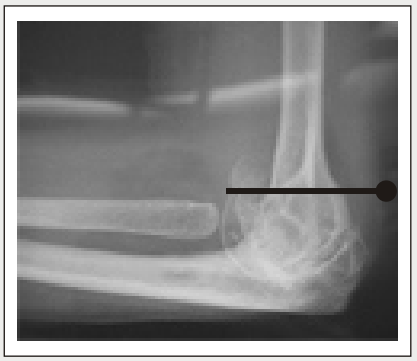

X-rays

(Fig.42)

MRI:

Magnetic and radio waves are used to create a computer image of soft tissue such as nerves and ligaments.

(Refer fig.43)

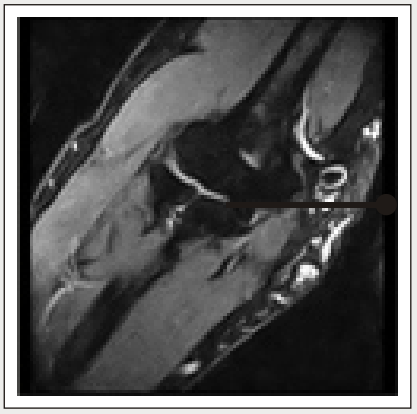

MRI

(Fig.43)

Ultrasonography:

A non-invasive test using sound waves to create computer images of soft structures such as tendons.

Injection Test:

A numbing agent, such as lidocaine, is injected into the medial epicondyle. If pain relief occurs, a diagnosis of medial Epicondylitis can be made.

Conservative Treatment Options

Your physician will recommend conservative treatment options to treat the symptoms associated with Golfer's Elbow. These may include the following:

Activity Restrictions:

Limit use and rest the arm from activities that worsen symptoms.

(Refer fig.44)

Activity Restrictions

(Fig.44)

Orthotics:

Splints or braces may be ordered to decrease stress on the injured tissues

(Refer fig.45)

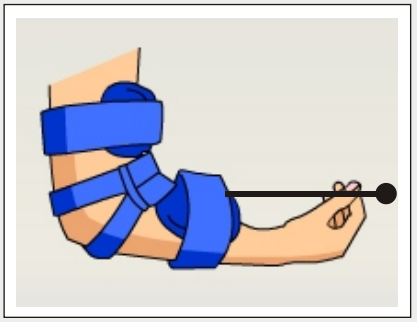

Orthotics

(Fig.45)

Ice:

Ice packs applied to the injury will help diminish swelling and pain. Ice should be applied over a towel to the affected area for 20 minutes four times a day for a couple days. Never place ice directly over the skin.

(Refer fig.46)

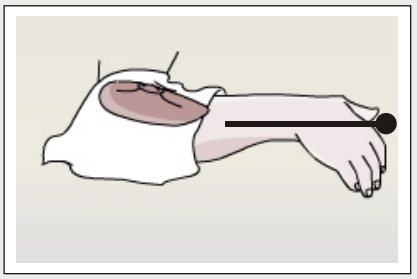

Ice

(Fig.46)

Medications:

Anti-inflammatory medications and/or steroid injections may be ordered to treat the pain and swelling.

(Refer fig.47)

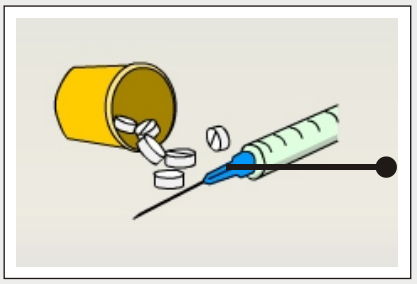

Medications

(Fig.47)

Occupational Therapy:

OT may be ordered for strengthening and stretching exercises to the forearm once your symptoms have decreased.

(Refer fig.48)

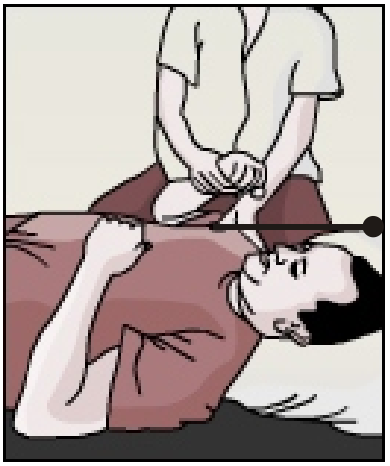

Occupational Therapy

(Fig.48)

Pulsed Ultrasound:

A non-invasive treatment used by therapists to break up scar tissue and increase blood flow to the injured tendons to promote healing.

(Refer fig.49)

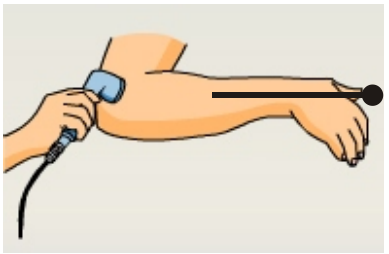

Pulsed Ultrasound

(Fig.49)

Professional instruction:

Consulting with a sports professional to assess and instruct in proper swing technique and appropriate equipment may be recommended to prevent recurrence.

(Refer fig.50)

Professional instruction

(Fig.50)

Surgical Procedure

Introduction:

If conservative treatment options fail to resolve the condition and symptoms persist for 6 -12 months, your surgeon may recommend surgery to treat Golfers Elbow.

It is important to understand that most cases of Golfer's elbow will resolve itself with adherence to your physician's treatment protocol. However, a small percentage of patients, less than 10%, may require surgical intervention despite adherence to the treatments ordered.

Surgical Treatment

The goal of surgery to treat Golfers Elbow is to remove the diseased tissue around the inner elbow, improve blood supply to the area to promote healing, and alleviate the patient's symptoms.

This surgery is performed in an operating room under regional or general anesthesia and is usually done as day surgery.

Surgical Procedure

Your surgeon will make an incision over the medial epicondyle area.

Soft tissues are moved aside for the surgeon to view where the tendon meets the medial epicondyle.

(Refer fig. "51 & 52")

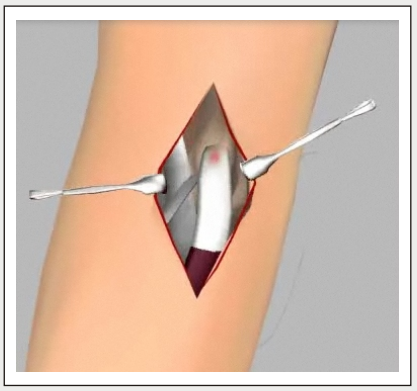

(Fig.51)

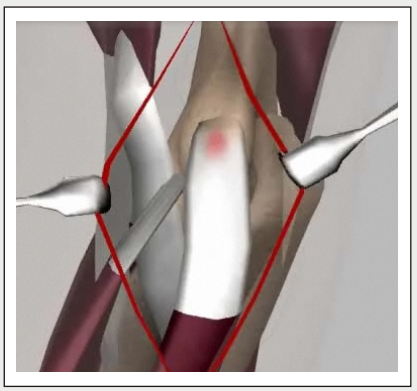

(Fig.52)

The surgeon will then cut the tendon and remove any scar tissue that is present. This is called Debridement of the tendon.

(Refer fig. "53 & 54")

If bone spurs is present on the medial epicondyle, these will be removed with special instruments.

The tendon is then reattached to the bone with special sutures.

The incision is closed with sutures.

(Refer fig. "55 & 56")

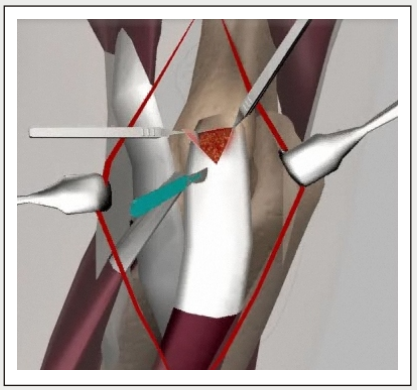

(Fig.53)

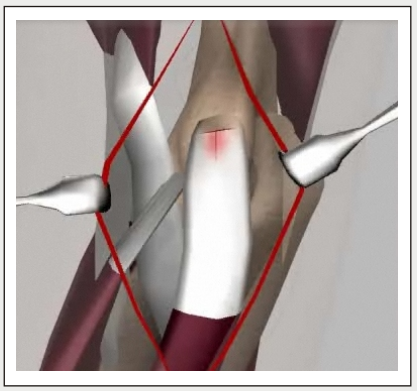

(Fig.54)

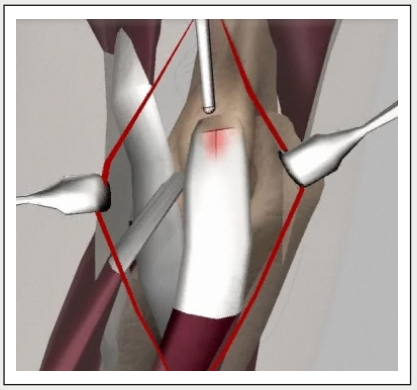

(Fig.55)

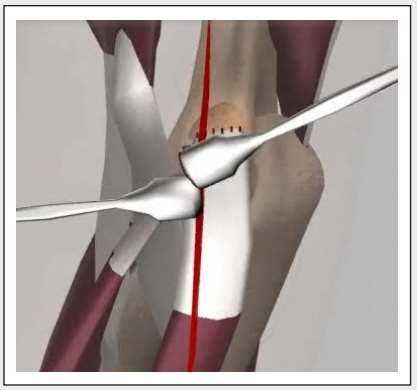

(Fig.56)

Surgical Procedure - Post Operative Care

After surgery your surgeon will give you guidelines to follow depending on the type of repair performed and the surgeon's preference.

Common Post-operative guidelines include:

- A sling, cast, or splint will be in place after surgery to keep the elbow immobilized.
- Elevating the elbow on pillows above the level of the heart is the most important thing you can do to reduce swelling.
- Flexing and opening your hand will also help to reduce swelling.
- Your surgeon may recommend applying ice packs to the area to help reduce swelling.
- Keep the incision area clean and dry. You may shower once the dressings are removed unless otherwise directed by your surgeon. If the arm is in a cast, cover the cast with plastic bags and tape to your skin above the cast to keep it dry when bathing.
- You will be given specific instructions regarding activity and rehabilitation.
- Occupational Therapy is usually ordered to restore elbow function and strength. It is imperative that you follow your exercise plan to improve motion and strength in the elbow.
- Your surgeon will prescribe pain medications to keep you comfortable at home.
- Eating a healthy diet and not smoking will promote healing.

Risks and Complications

As with any major surgery there are potential risks involved. The decision to proceed with the surgery is made because the advantages of surgery outweigh the potential disadvantages.

It is important that you are informed of these risks before the surgery takes place.

Complications can be medical (general) or specific to elbow surgery.

Medical complications include those of the anesthetic and your general well being. Almost any medical condition can occur so this list is not complete. Complications include:

- Allergic reactions to medications
- Blood loss requiring transfusion with its low risk of disease transmission
- Heart attacks, strokes, kidney failure, pneumonia, bladder infections
- Complications from nerve blocks such as infection or nerve damage
- Serious medical problems can lead to ongoing health concerns, prolonged hospitalization, or rarely death.

The majority of patients suffer no complications following Golfer's Elbow surgery, however, complications can occur following elbow surgery and include:

Excessive Elbow Stiffness

While some loss of motion to the elbow is normal, one of the most common risks following elbow surgery is excessive elbow stiffness. The main culprit for loss of extension is from the anterior capsule contracting due to the injury sustained during surgery. Scar tissue formation or extra bone growth in the soft tissue structures of the elbow joint can also contribute to excessive stiffness.

Infection

This is also rare but can occur during or after surgery. This may prolong your recovery, or require further surgery.

Nerve damage

The median, ulnar, and radial nerves pass closely over the elbow joint and lie very close to the incision site. Transient numbness and tingling of the fingers is not unusual after surgery and usually goes away in a few days. On rare occasions however, a nerve may be injured due to pressure from retractors or if the nerve is severed during the surgery. Trauma to the nerves can cause numbness, tingling, pain, and weakness.

Hematoma

A collection of blood caused by excess bleeding into the joint after the surgery is completed. This may require another surgery to irrigate the joint and evacuate the blood. This complication occurs more frequently in the obese patient due to the excess fat tissue.

Incision Breakdown

These can form in the arm muscles and can travel to the lung (Pulmonary embolism). These can be serious and even life threatening.

Symptoms Recur

Symptoms of Golfer's elbow may recur or not improve after the surgery.

Compartment Syndrome

This is a rare but dangerous condition that occurs when pressure inside the tissues is higher than the blood pressure of the vessels supplying nutrients to the tissues. This condition leads to muscle and possibly nerve death. Excessive swelling at the operative site causes compartment syndrome.

An early warning is if your splint, cast, or warp feels tight and your pain increases and is not controlled by your pain medication. Other possible symptoms include numbness and tingling in your fingers, cold fingers, or skin color changes. Call your surgeon immediately or go to the nearest emergency department if you experience these symptoms.

Risk factors that can negatively affect adequate healing after surgery include:

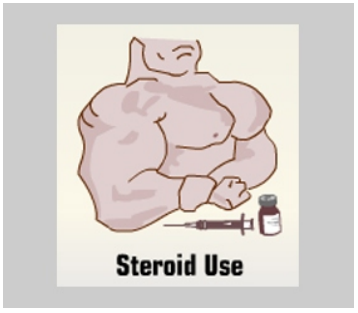

Although every effort is made to educate you on Golfer's Elbow, there will be specific information that will not be discussed. Talk to your doctor or health care provider about any questions you may have.

GHADIALI

Golfer's Elbow

Multimedia Health Education

☐ ☐ ☐ **YOUR SURGERY DATE**

☐ **READ YOUR BOOK AND MATERIAL**

☐ **VIEW YOUR VIDEO /CD / DVD / WEBSITE**

☐ **PRE - HABILITATION**

☐ **ARRANGE FOR BLOOD**

☐ **MEDICAL CHECK UP**

☐ **ADVANCE MEDICAL DIRECTIVE**

☐ **PRE - ADMISSION TESTING**

☐ **FAMILY SUPPORT REVIEW**

Physician's Name : _____

Physician's Signature: _____

Date : _____

Patient's Name : _____

Patient's Signature: _____

Date : _____