



# GHADIALI

## General Surgery

### P R E S E N T S

Dr. Mufa T. Ghadiali is skilled in all aspects of General Surgery.  
His General Surgery Services include:

- General Surgery
- Advanced Laparoscopic Surgery
- Surgical Oncology
- Gastrointestinal Surgery
- Hernia Surgery
- Endoscopy

## Knee Anatomy

Multimedia Health Education

### ***Disclaimer***

This movie is an educational resource only and should not be used to make a decision on Knee Replacement or about arthritis management. All decisions about Knee Replacement and management of arthritis must be made in conjunction with your surgeon or a licensed healthcare provider.

Mufa T. Ghadiali, M.D., F.A.C.S

Diplomate of American Board of Surgery

6405 North Federal Hwy., Suite 402  
Fort Lauderdale, FL 33308

Tel: 954-771-8888

Fax: 954- 491-9485

[www.ghadialisurgery.com](http://www.ghadialisurgery.com)

GHADIALI

## MULTIMEDIA HEALTH EDUCATION MANUAL

### TABLE OF CONTENTS

SECTION	CONTENT
<b>1 . Skeletal Anatomy</b>	
<b>2 . Soft Tissue Anatomy</b>	
<b>3 . Biomechanics</b>	

## INTRODUCTION

The information in this presentation has been intended to help consumers understand the structure and function of anatomical components and take charge of Orthopaedic health. The animated surgeries and procedures should help you understand Joint replacement procedures and help you to make a decision.

Also, it explains the risks, complications and provides guidelines for living with surgeries, conditions and procedures.

## Introduction

The knee joint, which appears like a simple hinge-joint, is one of the most complex joint. It consists of the femur (thighbone), tibia (shinbone) and patella (kneecap).

The knee is a synovial joint, which means it is lined by synovium. The synovium produces fluid lubricating and nourishing the inside of the joint.

Articular cartilage is the smooth surfaces at the end of the femur and tibia. It is the damage to this surface, which causes arthritis.

## Skeletal Anatomy

### Femur

The femur (thighbone) is the largest and the strongest bone in the body. It is the weight-bearing bone of the thigh. It provides attachment to most of the muscles of the knee.

(Refer fig.1)

### Condyle

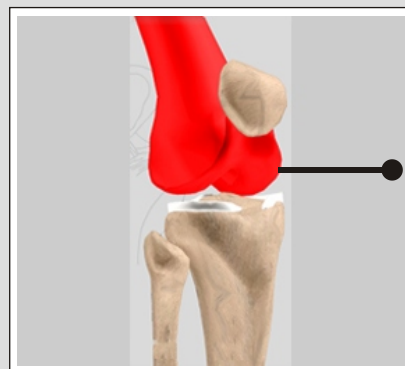
The two femoral condyles make up for the rounded end of femur. Its smooth articular surface allows the femur to move easily over the tibial (shinbone) meniscus.

(Refer fig.2)

### Tibia

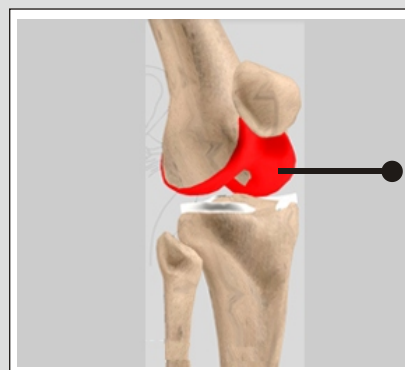
The tibia (shinbone) the second largest bone in the body is the weight bearing bone of the leg. The menisci incompletely cover the superior surface of the tibia where it articulates with the femur. The menisci act as shock absorbers, protecting the articular surface of the tibia as well as assisting in rotation of the knee.

(Refer fig. 3)



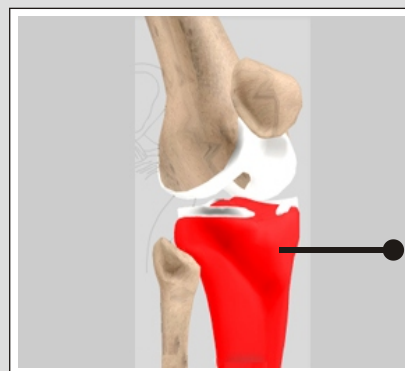
**Femur**

(Fig.1)



**Condyle**

(Fig. 2)



**Tibia**

(Fig. 3)

### Fibula

The fibula, although not a weight bearing bone, provides attachment sites for the Lateral Collateral Ligaments (LCL) and the biceps femoris tendon. The articulation of tibia and fibula, also allows a slight degree of movement, providing an element of flexibility in response to the actions of muscles attaching to the fibula.

*(Refer fig. 4)*

### Patella

The Patella (kneecap), attached to the quadriceps tendon above and the patellar ligament below, rests against the anterior articular surface of the lower end of the femur and protects the knee joint.

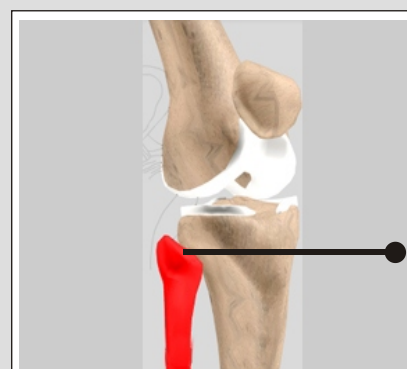
The patella acts as a fulcrum for the quadriceps by holding the quadriceps tendon off the lower end of the femur.

*(Refer fig. 5)*

### Menisci

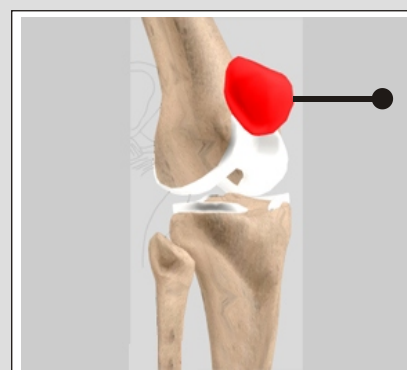The medial and the lateral meniscus are thin C-shaped layers of fibrocartilage, incompletely covering the surface of the tibia where it articulates with the femur. The majority of the meniscus has no blood supply and for that reason, when damaged the meniscus is unable to undergo the normal healing process that occurs in the rest of the body.

*(Refer fig. 6)*



**Fibula**

**(Fig. 4)**

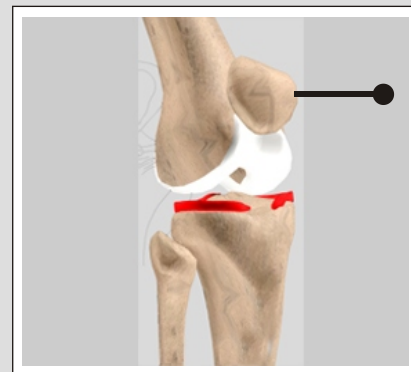


**Patella**

**(Fig. 5)**

## Menisci

In addition, meniscus begins to deteriorate with age, often developing degenerative tears. Typically, when the meniscus is damaged, the torn pieces begin to move in an abnormal fashion inside the joint.



**Menisci**

**(Fig. 6)**

The menisci act as shock absorbers, protecting the articular surface of the tibia as well as assisting in rotation of the knee. As secondary stabilizers, the intact menisci interact with the stabilizing function of the ligaments and are most effective when the surrounding ligaments are intact.

*(Refer fig. 6)*

### Unit 2:

### Soft Tissue Anatomy

#### Soft Tissue Anatomy

#### Anterior Cruciate Ligament (ACL)

The anterior cruciate ligament (ACL) is the major stabilizing ligament of the knee. The ACL is located in the center of the knee joint and runs from the femur (thigh bone) to the tibia (shin bone), through the center of the knee.

The ACL prevents the femur from sliding backwards on the tibia (or the tibia sliding forwards on the femur).

Together with Posterior Cruciate Ligament (PCL). ACL stabilizes the knee in a rotational fashion. Thus, if one of these ligaments is significantly damaged, the knee will be unstable when planting the foot of the injured extremity and pivoting, causing the knee to buckle and give way.

*(Refer fig. 7)*

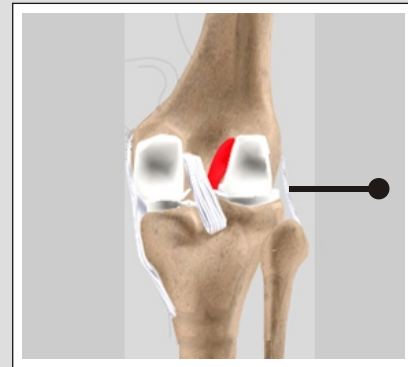
#### Posterior Cruciate Ligament (PCL)

Much less research has been done on the posterior cruciate ligament (PCL) because it is injured far less often than the ACL.

The PCL prevents the femur from moving too far forward over the tibia.

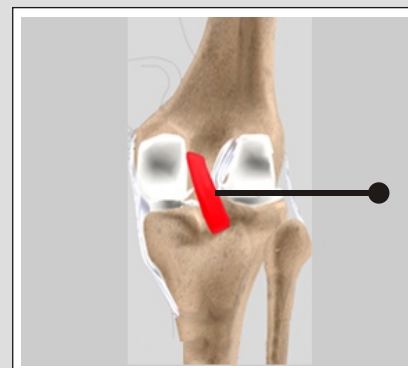
The PCL is the knee's basic stabilizer and is almost twice as strong as the ACL. It provides a central axis about which the knee rotates.

*(Refer fig. 8)*



**Anterior  
Cruciate  
Ligament (ACL)**

**(Fig. 7)**



**Posterior  
Cruciate  
Ligament (PCL)**

**(Fig. 8)**

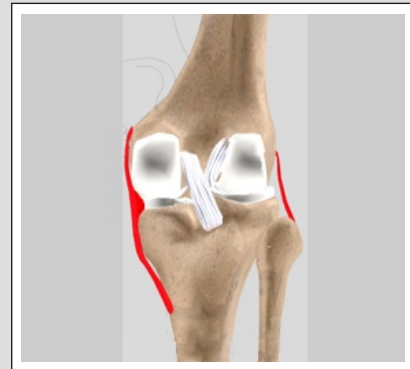
### Soft Tissue Anatomy

#### Collateral ligaments

Collateral Ligaments prevent hyperextension, adduction, and abduction.

- Superficial MCL (Medial Collateral Ligament) connects the medial (inner) epicondyle of the femur to the medial condyle of the tibia and resists valgus (bending out) force.
- Deep MCL (Medial Collateral Ligament) connects the medial (inner) epicondyle of the femur with the medial meniscus.
- LCL (Lateral Collateral Ligament), entirely separate from the articular capsule, connects the lateral (outer) epicondyle of the femur to the head of the fibula and resists varus (bending in) force.

(Refer fig. 9)



**Collateral ligaments**

**(Fig. 9)**



### Biomechanics of the Knee

The knee joint is a modified hinge joint. The active movements of the knee joint are described as flexion, extension, medial rotation and lateral rotation.

#### Flexion

When the knee is flexed or bent, the cruciate ligament is taut and the collateral ligaments are relaxed. Maximum flexion of the knee is 120-150 degrees.

(Refer fig. 10)

#### Extension

When the knee is extended or straightened, the lateral and medial collateral ligaments as well as the ACL are taut. Maximum extension of the knee is 5-10 degrees.

(Refer fig. 11)

#### Medial Rotation

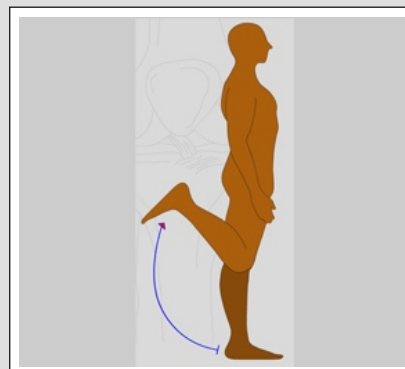
This movement can only be achieved while the knee is in flexion. The cruciate ligaments control medial rotation of the tibia by twisting around each other to enable this movement. Maximum internal rotation is 30-40 degrees.

(Refer fig. 12)

#### Lateral Rotation

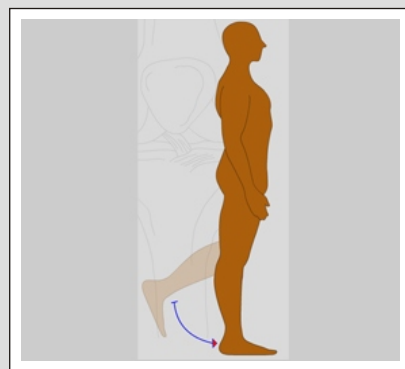
This movement also requires the knee to be flexed in order to rotate laterally. The cruciate ligaments control lateral rotation of the tibia by untwisting around each other to enable this movement. Maximum external rotation is 30-40 degrees.

(Refer fig. 13)



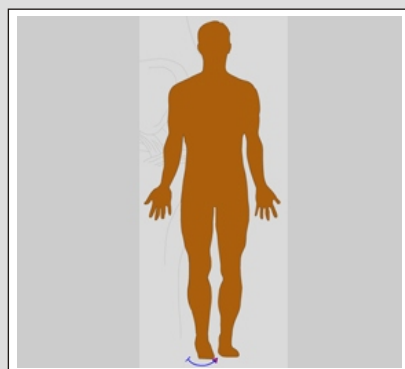
**Flexion**

(Fig. 10)



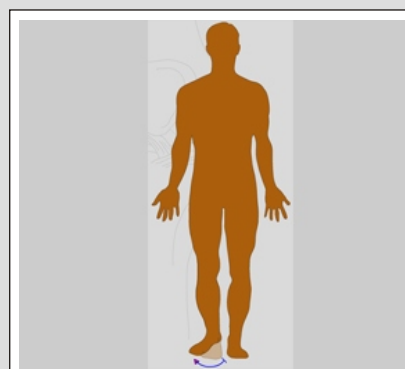
**Extension**

(Fig. 11)



**Medial  
Rotation**

(Fig. 12)



**Lateral  
Rotation**

(Fig. 13)

## Disclaimer

This movie is an educational resource only and should not be used to make a decision on Knee Replacement or about arthritis management. All decisions about Knee Replacement and management of arthritis must be made in conjunction with your surgeon or a licensed healthcare provider.

**YOUR SURGERY DATE**

**READ YOUR BOOK AND MATERIAL**

**VIEW YOUR VIDEO /CD / DVD / WEBSITE**

**PRE - HABILITATION**

**ARRANGE FOR BLOOD**

**MEDICAL CHECK UP**

**ADVANCE MEDICAL DIRECTIVE**

**PRE - ADMISSION TESTING**

**FAMILY SUPPORT REVIEW**

**Physician's Name :** \_\_\_\_\_

**Patient's Name :** \_\_\_\_\_

**Physician's Signature:** \_\_\_\_\_

**Patient's Signature:** \_\_\_\_\_

**Date :** \_\_\_\_\_

**Date :** \_\_\_\_\_