



GHADIALI

General Surgery

P R E S E N T S

Dr. Mufa T. Ghadiali is skilled in all aspects of General Surgery.
His General Surgery Services include:

- General Surgery
- Advanced Laparoscopic Surgery
- Surgical Oncology
- Gastrointestinal Surgery
- Hernia Surgery
- Endoscopy

Normal Anatomy of the Elbow

Multimedia Health Education

Disclaimer

This movie is an educational resource only and should not be used to manage Orthopaedic Health. All decisions about management of the elbow must be made in conjunction with your Physician or a licensed healthcare provider.

Mufa T. Ghadiali, M.D., F.A.C.S

Diplomate of American Board of Surgery

6405 North Federal Hwy., Suite 402
Fort Lauderdale, FL 33308

Tel: 954-771-8888

Fax: 954- 491-9485

www.ghadialisurgery.com

GHADIALI

MULTIMEDIA HEALTH EDUCATION MANUAL

TABLE OF CONTENTS

SECTION	CONTENT
1 . Introduction	
a. Skeletal Anatomy	
2 . Anatomy of the Elbow	
a. Soft Tissue Anatomy	
3 . Biomechanics of the Elbow	
a. Normal Movement	

Introduction

The elbow in the human body consists of:

- Bones
- Joints
- Muscle
- Ligaments and Tendons
- Numerous Blood vessels, nerves, and soft tissue

It is important to understand the normal anatomy of the elbow in order to learn about diseases and conditions that can affect our elbow.

Bones

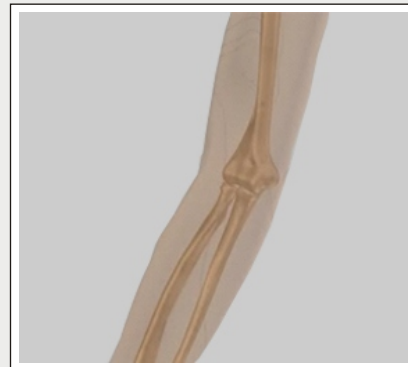(Refer fig.1)

Joints

(Refer fig. 2)

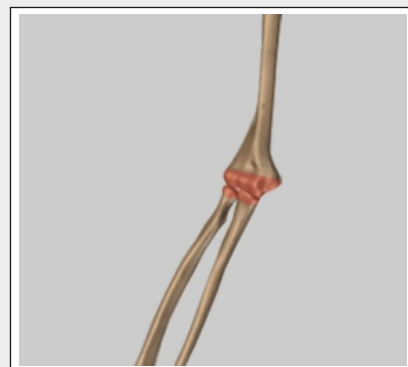
Muscles

(Refer fig. 3)




Bones

(Fig.1)



Joints

(Fig. 2)



Muscles

(Fig. 3)

Ligaments and Tendons

(Refer fig. 4)

Numerous Blood vessels, nerves, and soft tissue

(Refer fig. 5)

Normal Elbow Anatomy

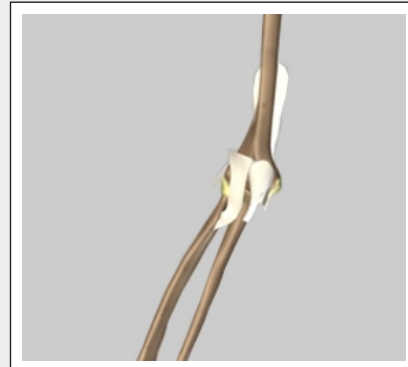
The arm in the human body is made up of three bones that join together to form a hinge joint called the elbow. The upper arm bone or humerus connects from the shoulder to the elbow forming the top of the hinge joint. The lower arm or forearm consists of two bones, the radius and the ulna. These bones connect the wrist to the elbow forming the bottom portion of the hinge joint.

The elbow joint is actually three separate joints surrounded by a watertight sac called a joint capsule. This capsule surrounds the elbow joint and contains lubricating fluid called synovial fluid.

- Humerus
- Ulna
- Radius


Humerus

(Refer fig. 6)



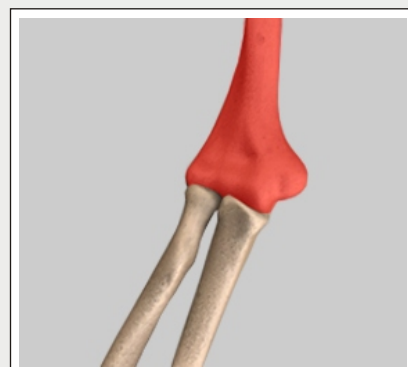
Ligaments and Tendons

(Fig. 4)



Ligaments and Tendons

(Fig. 5)

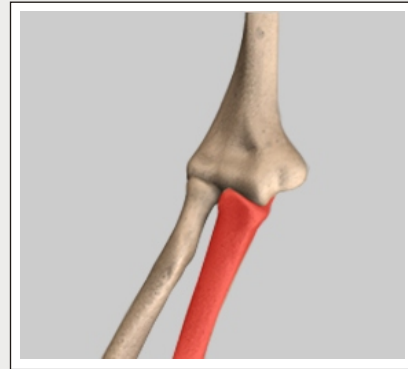


Humerus

(Fig. 6)

Ulna

(Refer fig. 7)

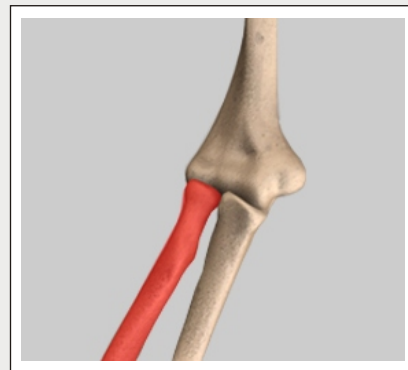


Ulna

(Fig. 7)

Radius

(Refer fig. 8)



Radius

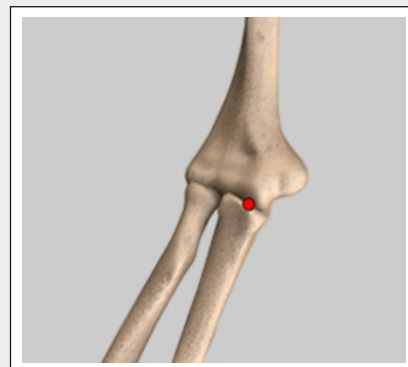
(Fig. 8)

The three joints of the elbow include:

Ulnohumeral

Ulnohumeral joint is where movement between the ulna and humerus occurs.

(Refer fig. 9)



Ulnohumeral

(Fig. 9)

Radiohumeral

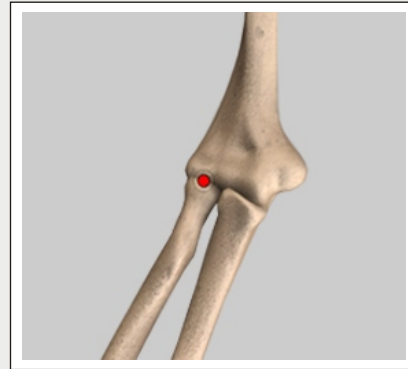
Radiohumeral joint is where movement between the radius and humerus occurs.

(Refer fig. 10)

Proximal radioulnar

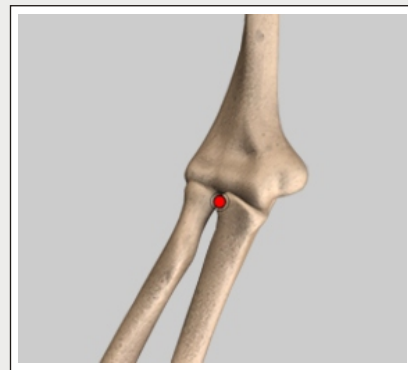
Proximal radioulnar joint is where movement between the radius and ulna occurs.

(Refer fig. 11)



Radiohumeral

(Fig. 10)



Proximal radioulnar

(Fig. 11)

Soft Tissue Anatomy

Our elbow is held in place and supported by various soft tissues.

Cartilage

Shiny and smooth, cartilage allows smooth movement where two bones come in contact with each other.

(Refer fig. 12)

Tendons

Tendons are soft tissue that connects muscles to bones to provide support.

(Refer fig. 13)

Biceps Tendon

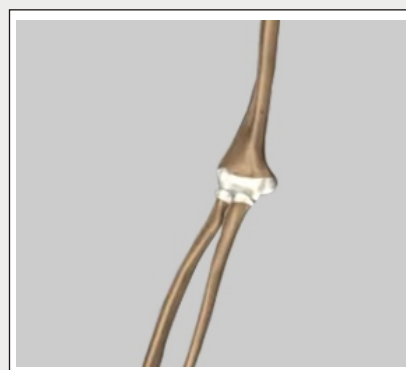
This tendon attaches the biceps muscle on the front of the arm to the radius allowing supination, rotation of the elbow.

(Refer fig. 14)

Triceps Tendon


This tendon attaches the triceps muscle on the back of the arm to the ulna bone allowing the elbow to straighten.

(Refer fig. 15)



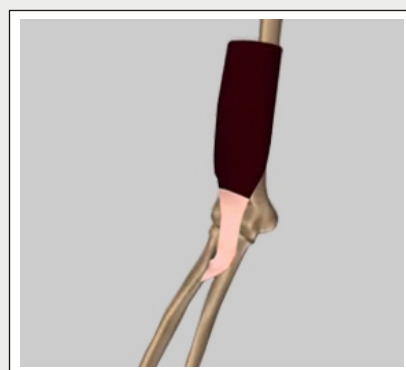
Cartilage

(Fig. 12)




Tendons

(Fig. 13)



Biceps Tendon

(Fig. 14)



Triceps Tendon

(Fig. 15)

Lateral Epicondyle

This bony prominence located just above the elbow on the outside is where the forearm muscles that straighten the fingers and wrist come together in one tendon to attach to the humerus.

(Refer fig. 16)

Medial Epicondyle


This bony prominence located just above the elbow on the inside is where the muscles that bend the fingers and wrist come together in one tendon to attach to the humerus.

(Refer fig. 17)

Ligaments


Ligaments are strong rope like tissue that connects bones to other bones and help hold tendons in place providing stability to joints. Ligaments around the elbow join to form a watertight sac called a joint capsule. This capsule surrounds the elbow joint and contains lubricating fluid called synovial fluid. There are four main ligaments in the elbow.

(Refer fig. 18)



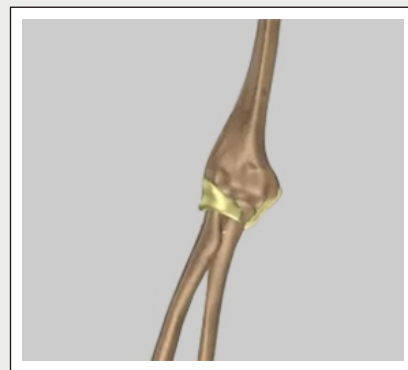Lateral Epicondyle

(Fig. 16)



Medial Epicondyle

(Fig. 17)



Ligaments

(Fig. 18)

Medial collateral ligament

Located on the inside of the elbow this ligament connects the ulna to the humerus.

(Refer fig. 19)

Lateral collateral ligament

Located on the outside of the elbow this ligament connects the radius to the humerus.

(Refer fig. 20)

Annular ligament

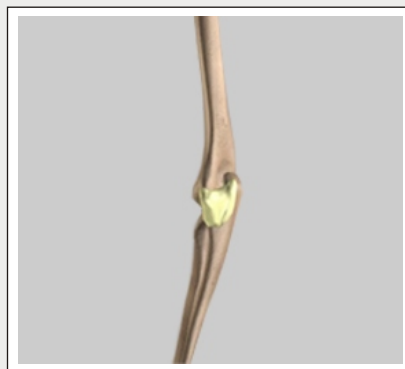
This ligament forms a ring around the head of the radius bone, holding it tight against the ulna.

(Refer fig. 21)

Quadrates ligament


This ligament also connects the radius to the ulna.

(Refer fig. 22)



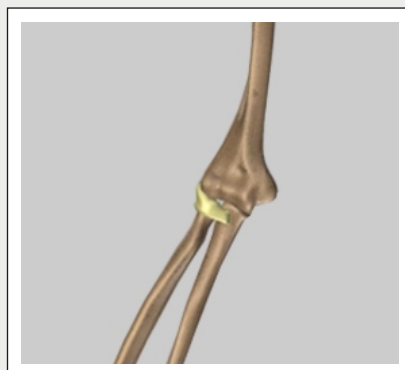
Medial collateral ligament

(Fig. 19)



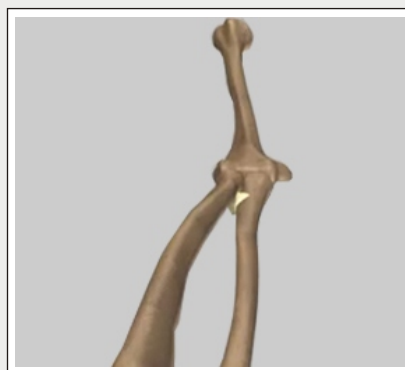
Lateral collateral ligament

(Fig. 20)



Annular ligament

(Fig. 21)



Quadrates ligament

(Fig. 22)

Unit 2:

Anatomy of the Elbow

Muscles

Muscles are fibrous tissue capable of contracting to cause body movement.

(Refer fig. 23)

Biceps

This is the large muscle on the front of the arm above the elbow that allows elbow supination, rotation of the elbow.

(Refer fig. 24)

Triceps


This is the large muscle on the back of the arm above the elbow enabling elbow extension, straightening of the elbow.

(Refer fig. 25)

Brachialis


This muscle is the primary elbow flexor enabling bending of the elbow. It is located at the distal end of the humerus.

(Refer fig. 26)




Muscles

(Fig. 23)



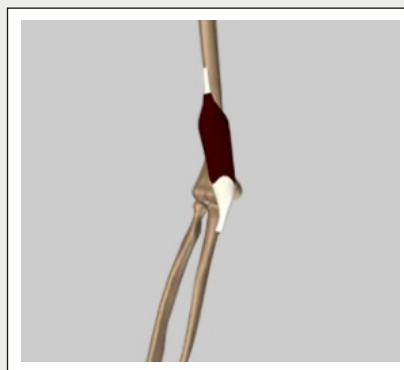
Biceps

(Fig. 24)



Triceps

(Fig. 25)



Brachialis

(Fig. 26)

Unit 2:

Anatomy of the Elbow

Wrist extensors

These muscles of the forearm attach to the lateral epicondyle enabling extension of the hand and wrist.

(Refer fig. 27)

Wrist flexors

These muscles of the forearm attach to the medial epicondyle enabling flexion of the hand and wrist.

(Refer fig. 28)

Nerves

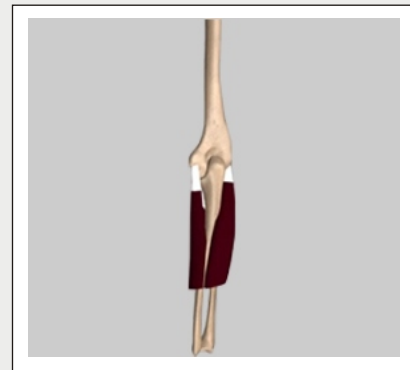
Nerves are responsible for carrying signals back and forth from the brain to muscles in our body, enabling movement and sensation such as touch, pain, and hot or cold.

(Refer fig. 29)

The three main nerves of the arm are:

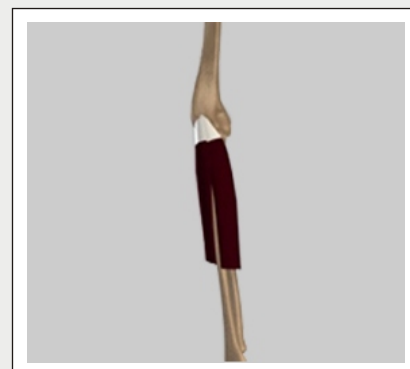- Radial nerve
- Ulnar nerve
- Median nerve

All three nerves begin at the shoulder and travel down the arm across the elbow.



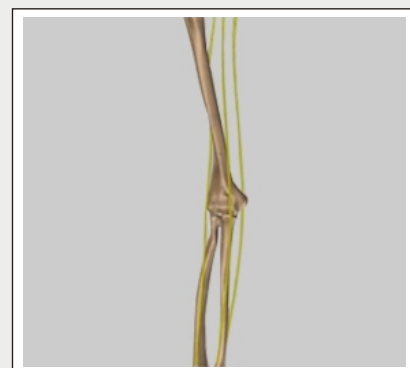
Wrist extensors

(Fig. 27)



Wrist flexors

(Fig. 28)



Nerves

(Fig. 29)

Blood Vessels

The main vessel of the arm is the brachial artery. This artery travels across the inside of the elbow at the bend and then splits into two branches below the elbow.

(Refer fig. 30)

These branches are:

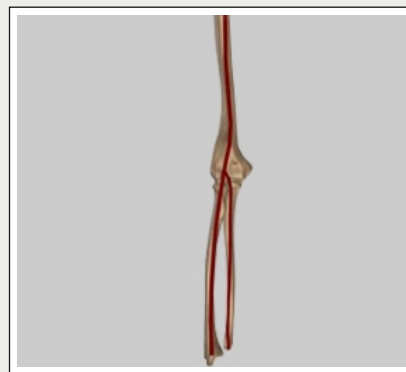Radial Artery: The radial artery is the largest artery supplying the hand and wrist area. Traveling across the front of the wrist, nearest the thumb, it is this artery that is palpated when a pulse is counted at the wrist.

Ulnar Artery: The ulnar artery travels next to the ulnar nerve through Guyon's canal in the wrist. It supplies blood flow to the front of the hand, fingers and thumb.

Bursae

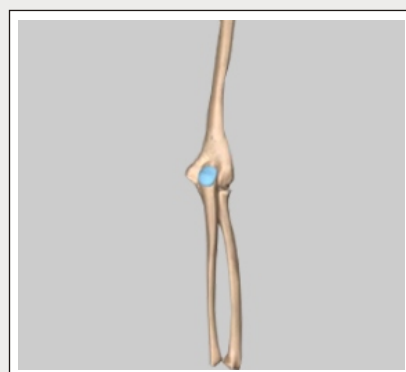Bursae are small fluid filled sacs that decrease friction between tendons and bone or skin. Bursae contain special cells called synovial cells that secrete a lubricating fluid. When this fluid becomes infected, a common painful condition known as Bursitis can develop.

(Refer fig. 31)



Blood Vessels

(Fig. 30)



Bursae

(Fig. 31)

Normal Movement

Biomechanics

Biomechanics is a term to describe movement of the body.

(Refer fig. 32)

Flexion

Bending the elbow (bringing the forearm towards the upper arm) occurs at the ulnohumeral and radiohumeral joints.

(Refer fig. 33)

Extension

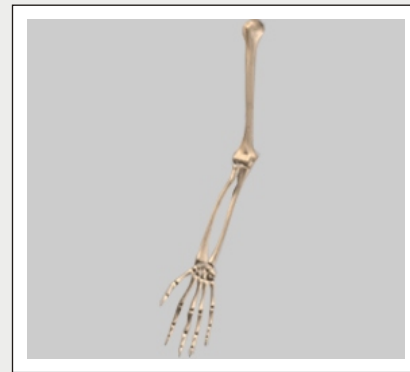Straightening the elbow (bringing the forearm away from the upper arm) also occurs at the ulnohumeral and radiohumeral joints.

(Refer fig. 34)

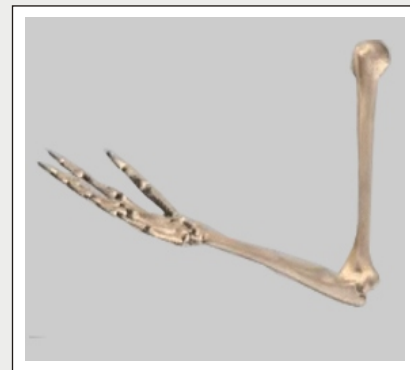Pronation

This movement is rotation of the forearm that moves the palm to a face down position. It occurs at the articulation between the radius and ulna, the proximal radioulnar joint.

(Refer fig. 35)

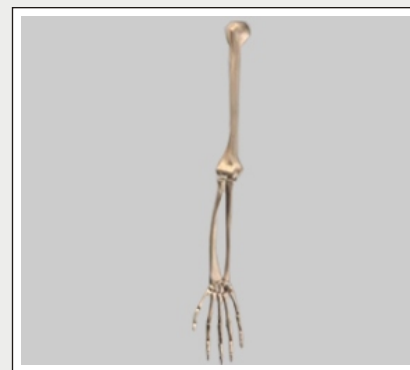

(Fig. 32)



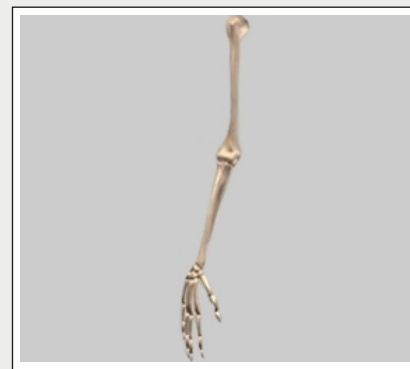Flexion

(Fig. 33)



Extension

(Fig. 34)



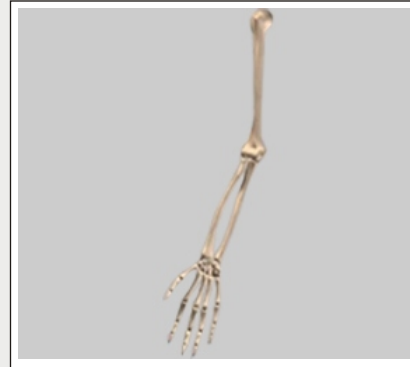Pronation

(Fig. 35)

Supination

This movement is rotation of the forearm so that the palm faces up. This also occurs at the proximal radioulnar joint.

(Refer fig. 36)



Supination

(Fig. 36)

Disclaimer

Although every effort is made to educate you on normal anatomy of the Elbow, there will be specific information that will not be discussed. Talk to your doctor or health care provider about any questions you may have.

YOUR SURGERY DATE

READ YOUR BOOK AND MATERIAL

VIEW YOUR VIDEO /CD / DVD / WEBSITE

PRE - HABILITATION

ARRANGE FOR BLOOD

MEDICAL CHECK UP

ADVANCE MEDICAL DIRECTIVE

PRE - ADMISSION TESTING

FAMILY SUPPORT REVIEW

Physician's Name : _____

Patient's Name : _____

Physician's Signature: _____

Patient's Signature: _____

Date : _____

Date : _____